

# Testicular Cancer, Version 2.2020

Timothy Gilligan, MD<sup>1</sup>; Daniel W. Lin, MD<sup>2</sup>; Rahul Aggarwal, MD<sup>3</sup>; David Chism, MD, MS<sup>4</sup>; Nicholas Cost, MD<sup>5</sup>; Ithaa H. Derweesh, MD<sup>6</sup>; Hamid Enamekhoo, MD<sup>7</sup>; Darren R. Feldman, MD<sup>8</sup>; Daniel M. Geynisman, MD<sup>9</sup>; Steven L. Hancock, MD<sup>10</sup>; Chad LaGrange, MD<sup>11</sup>; Ellis G. Levine, MD<sup>12</sup>; Thomas Longo, MD<sup>13</sup>; Will Lowrance, MD, MPH<sup>14</sup>; Bradley McGregor, MD<sup>15</sup>; Paul Monk, MD<sup>16</sup>; Joel Picus, MD<sup>17</sup>; Phillip Pierorazio, MD<sup>18</sup>; Soroush Rais-Bahrami, MD<sup>19</sup>; Philip Saylor, MD<sup>20</sup>; Kanishka Sircar, MD<sup>21</sup>; David C. Smith, MD<sup>22</sup>; Katherine Tzou, MD<sup>23</sup>; Daniel Vaena, MD<sup>24</sup>; David Vaughn, MD<sup>25</sup>; Kosj Yamoah, MD, PhD<sup>26</sup>; Jonathan Yamzon, MD<sup>27</sup>; Alyse Johnson-Chilla, MS<sup>28</sup>; Jennifer Keller, MSS<sup>28</sup>; and Lenora A. Pluchino, PhD<sup>28</sup>

## ABSTRACT

Testicular cancer is relatively uncommon and accounts for <1% of all male tumors. However, it is the most common solid tumor in men between the ages of 20 and 34 years, and the global incidence has been steadily rising over the past several decades. Several risk factors for testicular cancer have been identified, including personal or family history of testicular cancer and cryptorchidism. Testicular germ cell tumors (GCTs) comprise 95% of malignant tumors arising in the testes and are categorized into 2 main histologic subtypes: seminoma and nonseminoma. Although nonseminoma is the more clinically aggressive tumor subtype, 5-year survival rates exceed 70% with current treatment options, even in patients with advanced or metastatic disease. Radical inguinal orchiectomy is the primary treatment for most patients with testicular GCTs. Postorchiectomy management is dictated by stage, histology, and risk classification; treatment options for nonseminoma include surveillance, systemic therapy, and nerve-sparing retroperitoneal lymph node dissection. Although rarely occurring, prognosis for patients with brain metastases remains poor, with >50% of patients dying within 1 year of diagnosis. This selection from the NCCN Guidelines for Testicular Cancer focuses on recommendations for the management of adult patients with non-seminomatous GCTs.

*J Natl Compr Canc Netw* 2019;17(12):1529–1554  
doi: 10.6004/jnccn.2019.0058

<sup>1</sup>Case Comprehensive Cancer Center/University Hospitals Seidman Cancer Center and Cleveland Clinic Taussig Cancer Institute; <sup>2</sup>University of Washington/Seattle Cancer Care Alliance; <sup>3</sup>UCSF Helen Diller Family Comprehensive Cancer Center; <sup>4</sup>Vanderbilt-Ingram Cancer Center; <sup>5</sup>University of Colorado Cancer Center; <sup>6</sup>UC San Diego Moores Cancer Center; <sup>7</sup>University of Wisconsin Carbone Cancer Center; <sup>8</sup>Memorial Sloan Kettering Cancer Center; <sup>9</sup>Fox Chase Cancer Center; <sup>10</sup>Stanford Cancer Institute; <sup>11</sup>Fred & Pamela Buffett Cancer Center; <sup>12</sup>Roswell Park Cancer Institute; <sup>13</sup>Duke Cancer Institute; <sup>14</sup>Huntsman Cancer Institute at the University of Utah; <sup>15</sup>Dana-Farber/Brigham and Women's Cancer Center; <sup>16</sup>The Ohio State University Comprehensive Cancer Center - James Cancer Hospital and Solove Research Institute; <sup>17</sup>Siteman Cancer Center at Barnes-Jewish Hospital and Washington University School of Medicine; <sup>18</sup>The Sidney Kimmel Comprehensive Cancer Center at Johns Hopkins; <sup>19</sup>O'Neal Comprehensive Cancer Center at UAB; <sup>20</sup>Massachusetts General Hospital Cancer Center; <sup>21</sup>The University of Texas MD Anderson Cancer Center; <sup>22</sup>University of Michigan Rogel Cancer Center; <sup>23</sup>Mayo Clinic Cancer Center; <sup>24</sup>St. Jude Children's Research Hospital/The University of Tennessee Health Science Center; <sup>25</sup>Abramson Cancer Center at the University of Pennsylvania; <sup>26</sup>Moffitt Cancer Center; <sup>27</sup>City of Hope National Medical Center; and <sup>28</sup>National Comprehensive Cancer Network.

## NCCN CATEGORIES OF EVIDENCE AND CONSENSUS

**Category 1:** Based upon high-level evidence, there is uniform NCCN consensus that the intervention is appropriate.

**Category 2A:** Based upon lower-level evidence, there is uniform NCCN consensus that the intervention is appropriate.

**Category 2B:** Based upon lower-level evidence, there is NCCN consensus that the intervention is appropriate.

**Category 3:** Based upon any level of evidence, there is major NCCN disagreement that the intervention is appropriate.

**All recommendations are category 2A unless otherwise noted.**

**Clinical trials:** NCCN believes that the best management of any patient with cancer is in a clinical trial. Participation in clinical trials is especially encouraged.

## PLEASE NOTE

The NCCN Clinical Practice Guidelines in Oncology (NCCN Guidelines<sup>®</sup>) are a statement of evidence and consensus of the authors regarding their views of currently accepted approaches to treatment. Any clinician seeking to apply or consult the NCCN Guidelines is expected to use independent medical judgment in the context of individual clinical circumstances to determine any patient's care or treatment. The National Comprehensive Cancer Network<sup>®</sup> (NCCN<sup>®</sup>) makes no representations or warranties of any kind regarding their content, use, or application and disclaims any responsibility for their application or use in any way.

**The complete NCCN Guidelines for Testicular Cancer are not printed in this issue of JNCCN but can be accessed online at NCCN.org.**

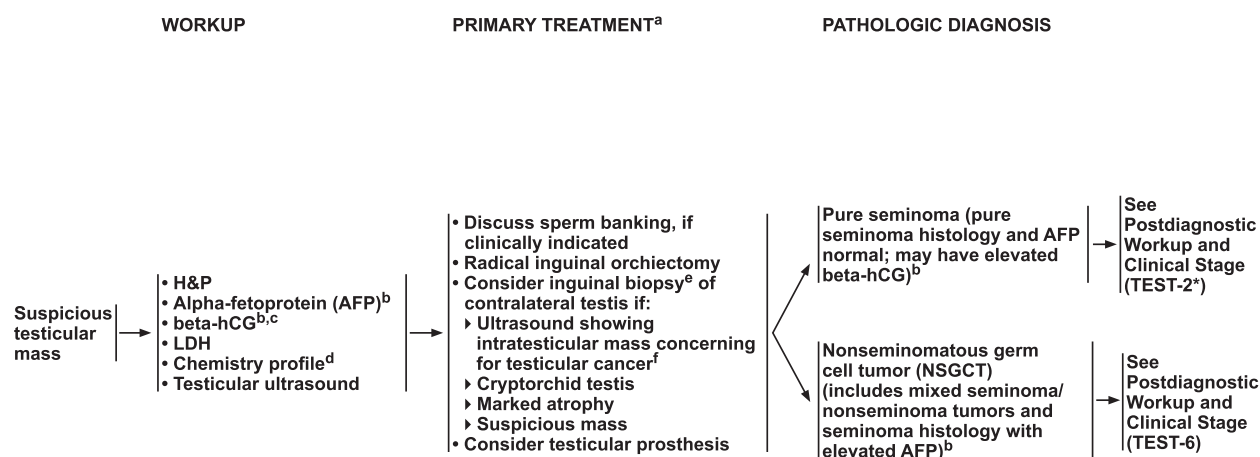
© National Comprehensive Cancer Network, Inc. 2019. All rights reserved. The NCCN Guidelines and the illustrations herein may not be reproduced in any form without the express written permission of NCCN.

## Disclosures for the NCCN Testicular Cancer Panel

At the beginning of each NCCN Guidelines Panel meeting, panel members review all potential conflicts of interest. NCCN, in keeping with its commitment to public transparency, publishes these disclosures for panel members, staff, and NCCN itself.

Individual disclosures for the NCCN Testicular Cancer Panel members can be found on page 1554. (The most recent version of these guidelines and accompanying disclosures are available at NCCN.org.)

**The complete and most recent version of these guidelines is available free of charge at NCCN.org.**



<sup>a</sup> Though rare, when a patient presents with rapidly increasing beta-hCG or AFP and symptoms related to disseminated disease with a testicular mass, chemotherapy can be initiated immediately without waiting for a biopsy diagnosis or performing orchiectomy.

<sup>b</sup> Mildly elevated, non-rising AFP levels may not indicate presence of germ cell tumor. Decisions to treat should not be based on AFP values <20 ng/mL. Further workup should be considered before initiating treatment for mildly elevated beta-hCG (generally <20 IU/L) since other factors, including hypogonadism and marijuana use, can cause false-positive results. See Discussion.

<sup>c</sup> Quantitative analysis of beta subunit.

<sup>d</sup> Consider measuring baseline levels of gonadal function.

<sup>e</sup> Inguinal exploration with exposure of testis, with direct observation and directed biopsy.

<sup>f</sup> Biopsies are not recommended for microcalcifications.

\*Available online, in these guidelines, at NCCN.org.

Version 2.2020, 11/20/19 © National Comprehensive Cancer Network, Inc. 2019. All rights reserved. The NCCN Guidelines® and this illustration may not be reproduced in any form without the express written permission of NCCN.

TEST-1

## Overview

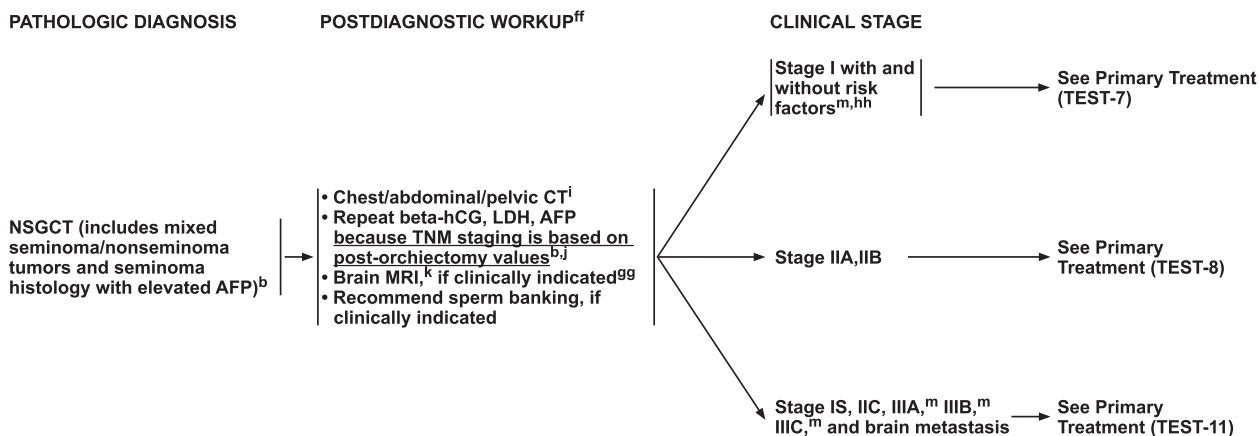
Testicular cancer is relatively uncommon and accounts for <1% of all male tumors.<sup>1</sup> However, it is the most common solid tumor in men between the ages of 20 and 34 years, and the global incidence has been steadily rising over the past several decades.<sup>1-7</sup> An estimated 9,560 new cases of testicular cancer will be diagnosed in the United States in 2019, resulting in approximately 410 deaths, which reflects the excellent 5-year survival rate for this disease (~95%).<sup>1,8</sup> Several risk factors for testicular cancer have been identified, including personal or family history of testicular cancer and cryptorchidism.<sup>2,9,10</sup>

Testicular germ cell tumors (GCTs) comprise 95% of malignant tumors arising in the testes and are categorized into 2 main histologic subtypes: seminoma and nonseminoma.<sup>2,11,12</sup> Nonseminomas are less common but are more aggressive and often include multiple cell types. When both seminoma and elements of nonseminoma are present, management follows that of a nonseminoma. The 4 types of nonseminomas are embryonal carcinoma, choriocarcinoma, yolk sac tumor, and teratoma.<sup>11</sup> Most nonseminomas are mixed tumors of these 4 subtypes. Teratomas are sometimes classified

as either mature or immature, but this distinction is of no known significance in adult men and does not affect management in these patients. Rarely, a teratoma may contain elements of a somatic cancer, such as a sarcoma or adenocarcinoma, and it is then referred to as a “teratoma with somatic type malignancy.”

Teratomas with somatic transformation are managed somewhat differently from other nonseminomatous GCTs. For example, stage I transformed teratoma is preferentially managed with retroperitoneal lymph node dissection (RPLND) whereas other stage I nonseminomas are typically managed using surveillance.

The serum tumor markers alpha-fetoprotein (AFP) and beta-human chorionic gonadotropin (beta-hCG) are critical in determining prognosis and assessing treatment outcomes in patients with testicular GCTs. These serum tumor markers should be determined before and after treatment and throughout the follow-up period. In addition, lactate dehydrogenase (LDH) is important for determining prognosis and is used to help risk-stratify patients starting first-line chemotherapy for disseminated nonseminomatous tumors.<sup>13</sup> Although serum LDH concentrations are elevated in about half of men with advanced testicular cancer, LDH is a less specific marker



<sup>b</sup> Mildly elevated, non-rising AFP levels may not indicate presence of germ cell tumor. Decisions to treat should not be based on AFP values <20 ng/mL. Further workup should be considered before initiating treatment for mildly elevated beta-hCG (generally <20 IU/L) since other factors, including hypogonadism and marijuana use, can cause false-positive results. See Discussion.

<sup>i</sup> With contrast.

<sup>j</sup> Elevated values should be followed after orchiectomy with repeated determination to allow precise staging. Follow declining markers until normalization or plateau. Staging is based on marker levels at the time that the patient starts postorchietomy therapy (for example, for patients starting chemotherapy for disseminated disease, prognostic category and staging should be assigned based on the serum tumor marker levels on day 1 of cycle 1 of chemotherapy).

<sup>k</sup> With and without contrast.

<sup>m</sup> The panel recommends staging tumors with discontinuous invasion of the spermatic cord as pT3 (high-risk stage I) and not as M1 (stage III) as is recommended in the 8th edition of the AJCC Cancer Staging Manual. If surveillance is elected, the pelvis should be included in the imaging due to a higher risk of pelvic relapses in these patients. See Discussion.

<sup>ff</sup> PET/CT scan is not clinically indicated for nonseminoma.

<sup>gg</sup> Eg, beta-hCG >5000 IU/L, extensive lung metastasis, choriocarcinoma, neurologic symptoms, non-pulmonary visceral metastasis, or AFP >10,000 ng/mL.

<sup>hh</sup> Risk factors include lymphovascular invasion or invasion of spermatic cord or scrotum. Some centers consider predominance of embryonal carcinoma as an additional risk factor for relapse.

Version 2.2020, 11/20/19 © National Comprehensive Cancer Network, Inc. 2019. All rights reserved. The NCCN Guidelines® and this illustration may not be reproduced in any form without the express written permission of NCCN.

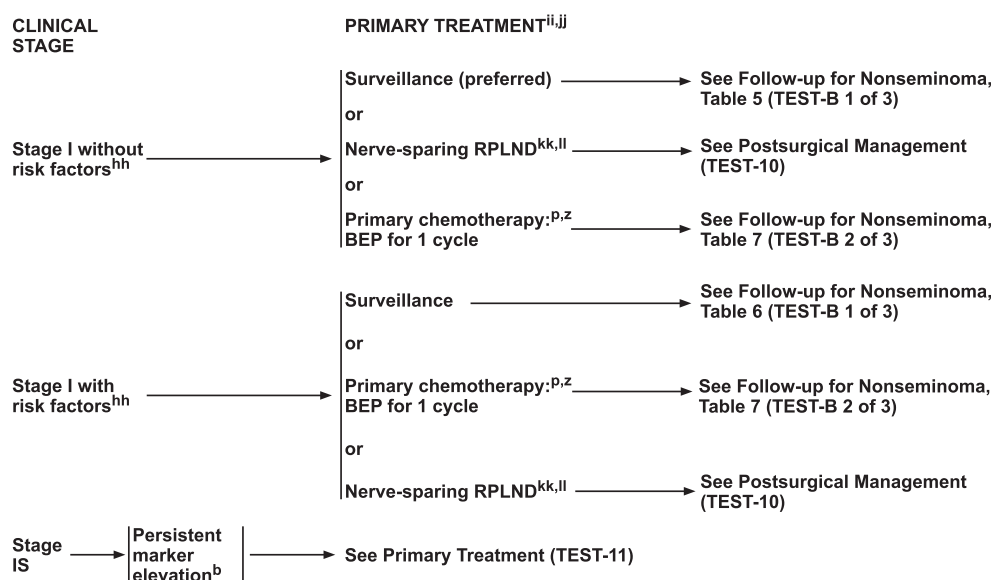
TEST-6

for testicular cancer compared with AFP and beta-hCG. Therefore, decisions regarding treatment should not be made based on mildly elevated (<3 × upper limit of normal) LDH alone.

Beta-hCG is the most commonly elevated serum tumor marker in testicular cancer. Elevated serum concentrations of beta-hCG may be present with both seminomatous and nonseminomatous tumors. However, in patients with seminoma with beta-hCG levels >1,000 IU/L, consider the possibility of nonseminoma and re-review the surgical specimen with pathology. Discussion with a high-volume center experienced in the management of these patients should also be considered. Additionally, patients with postorchietomy beta-hCG levels >5,000 IU/L should undergo brain MRI because they are at an increased risk of having brain metastases. Further workup should be considered before starting treatment of mildly elevated beta-hCG (generally <20 IU/L), because other factors such as hypogonadism, hyperthyroidism, and marijuana use can cause elevations of beta-hCG.<sup>14–16</sup> Intramuscular injection of 300 mg of testosterone cypionate may be administered in cases of mild beta-hCG elevations of unclear etiology to exclude hypogonadism as a cause. Elevated beta-hCG has also been reported in other tumors, such as lymphoma,

bladder cancer, and adenocarcinomas, and is thus not specific for germ cell malignancies. Additionally, heterophile antibodies have been reported to result in substantially elevated false-positive beta-hCG results (>400 IU/L), so clinicians should consider repeating the test using a different assay if a false-positive result is suspected due to the absence of radiographic evidence of disease.<sup>17,18</sup>

Elevated serum AFP is not associated with pure seminoma. Among nonseminomas, it is particularly associated with yolk sac tumors but can also be produced by embryonal carcinomas and teratoma. When patients with a histologically “pure” seminoma have an elevated level of AFP, it is generally interpreted as meaning the tumor is a mixed GCT and that undetected non-seminomatous elements are present in addition to the seminoma.<sup>13,19–21</sup> However, a small number of people have a chronically elevated serum AFP level, and clinicians should be cautious about starting treatment for a mildly elevated but stable AFP level. In addition, other tumors such as hepatocellular carcinoma and gastric carcinomas can cause AFP elevation. If an elevation of serum AFP is due to a metastatic nonseminomatous GCT, then the AFP typically will be steadily rising. Generally, decisions to treat should not be based solely on AFP values <20 ng/mL.



<sup>b</sup> Mildly elevated, non-rising AFP levels may not indicate presence of germ cell tumor. Decisions to treat should not be based on AFP values <20 ng/mL. Further workup should be considered before initiating treatment for mildly elevated beta-hCG (generally <20 IU/L) since other factors, including hypogonadism and marijuana use, can cause false-positive results. See Discussion.

<sup>p</sup> Recommend abdomen/pelvic CT scan and chest x-ray or CT scan within the 4 weeks prior to the initiation of chemotherapy to confirm staging, even if scan was done previously. See Principles of Imaging (TEST-I).

<sup>z</sup> See Primary Chemotherapy Regimens for Germ Cell Tumors (TEST-E).

<sup>hh</sup> Risk factors include lymphovascular invasion or invasion of spermatic cord or scrotum. Some centers consider predominance of embryonal carcinoma as an additional risk factor for relapse.

<sup>ii</sup> Treatment options listed based on preference. See Discussion.

<sup>jj</sup> Retroperitoneal lymph node dissection (RPLND) is preferred as primary treatment for tumors with transformed teratoma. Patients with stage I pure teratoma and normal markers should receive either surveillance or RPLND. See Discussion.

<sup>kk</sup> RPLND is recommended within 4 weeks of CT scan and 7–10 days of marker measurement.

<sup>ll</sup> See Principles of Surgery for Germ Cell Tumors (TEST-H\*).

\*Available online, in these guidelines, at NCCN.org.

Version 2.2020, 11/20/19 © National Comprehensive Cancer Network, Inc. 2019. All rights reserved. The NCCN Guidelines® and this illustration may not be reproduced in any form without the express written permission of NCCN.

TEST-7

This selection from the NCCN Clinical Practice Guidelines in Oncology (NCCN Guidelines) for Testicular Cancer focuses on the diagnosis and management of nonseminomatous GCTs (to view the complete and most recent version of these guidelines, visit NCCN.org).

## Clinical Presentation, Workup, and Primary Treatment

### Clinical Presentation

Testicular cancer most often presents as a painless or painful testicular nodule, mass, enlargement, or induration (hardening). Often, patients will present with testicular discomfort or swelling suggestive of epididymitis or orchitis. A trial of antibiotics is never warranted in a man with a mass suspicious for GCT but can be considered in men with pain without a mass on further workup. Other patients may present with enlarged lymph nodes of the lower neck or upper chest supraclavicular), a retroperitoneal mass, gynecomastia, venous thrombosis, or pulmonary embolism.

### Workup

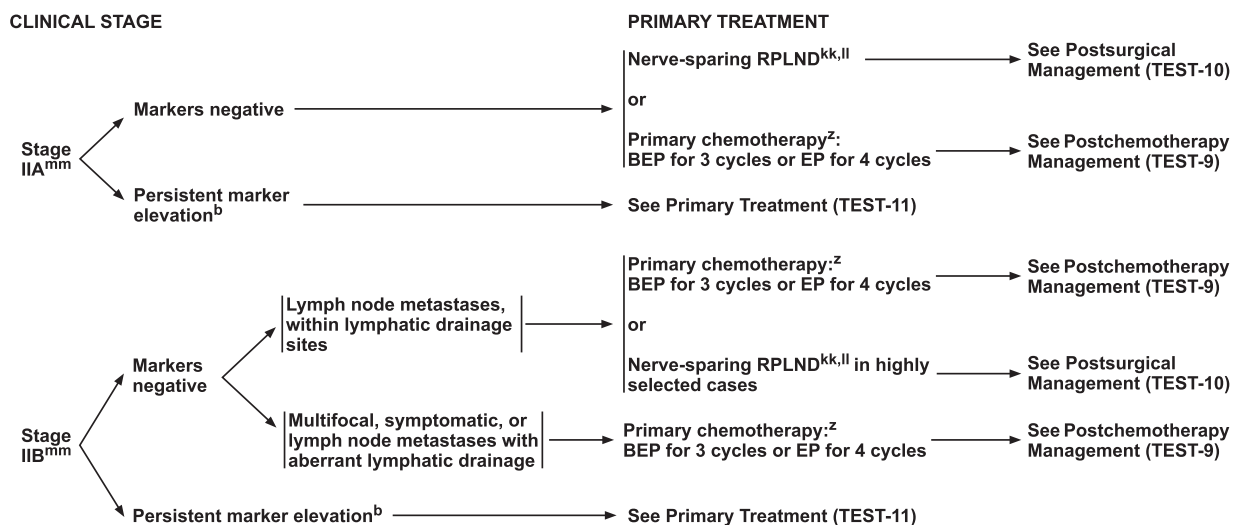
If testicular cancer is being considered as a possibility, then a transscrotal ultrasound with Doppler should be

performed (see TEST-1, page 1530). Testicular ultrasound serves to confirm the presence of a testicular mass, determine whether a mass is intra- or extratesticular, and to explore the contralateral testis.<sup>22</sup> Testicular GCTs are typically heterogeneous, hypoechoic, and vascular on ultrasound. If the ultrasound findings show a mass concerning for malignancy, then an inguinal orchiectomy is generally performed to make a diagnosis. Transscrotal biopsies of the testes should not be performed because violating the scrotum increases the risk of local or atypical regional recurrence and can complicate management. In addition, a thorough history and physical examination should be performed. Serum tumor markers, including LDH, AFP, and beta-hCG, need to be assessed as they are used for prognosis and staging.<sup>12</sup> Marker levels should be assessed both before and after orchiectomy. Elevated levels of beta-hCG, LDH, or AFP should be followed up with repeated tests to allow precise staging. Given the higher rates of hypogonadism in the testicular cancer population, measuring baseline levels of gonadal function can also be considered.

### Primary Treatment

Radical inguinal orchiectomy is the primary treatment for most patients who present with a testicular mass that





\*Available online, in these guidelines, at NCCN.org.

<sup>b</sup> Mildly elevated, non-rising AFP levels may not indicate presence of germ cell tumor. Decisions to treat should not be based on AFP values <20 ng/mL. Further workup should be considered before initiating treatment for mildly elevated beta-hCG (generally <20 IU/L) since other factors, including hypogonadism and marijuana use, can cause false-positive results. See Discussion.

<sup>z</sup> See Primary Chemotherapy Regimens for Germ Cell Tumors (TEST-E).

<sup>kk</sup> RPLND is recommended within 4 weeks of CT scan and 7–10 days of marker measurement.

<sup>ll</sup> See Principles of Surgery for Germ Cell Tumors (TEST-H\*).

<sup>mm</sup> RPLND is preferred as primary treatment for stage II tumors with transformed teratoma, and should be considered for stage II tumors with teratoma predominance in patients with normal markers. See Discussion.

Version 2.2020, 11/20/19 © National Comprehensive Cancer Network, Inc. 2019. All rights reserved.  
The NCCN Guidelines® and this illustration may not be reproduced in any form without the express written permission of NCCN.

TEST-8

is concerning for malignancy on ultrasound (see TEST-1, page 1530).<sup>23</sup> Concurrent insertion of testicular prosthesis may be considered during radical inguinal orchiectomy if desired by the patient.<sup>24–26</sup> In cases in which ultrasound shows an ambiguous abnormality that might be malignant, an open inguinal biopsy (testis-sparing surgery or partial orchiectomy) with intra-operative frozen section analysis can be performed, but such cases are extremely rare. Reflex orchiectomy is recommended in most circumstances should malignancy be detected. Similarly, an open inguinal biopsy of the contralateral testis can be considered if an ambiguous suspicious mass is identified on ultrasound or if the testis is cryptorchid or shows marked atrophy.<sup>27</sup> However, biopsies are not recommended for microcalcifications.

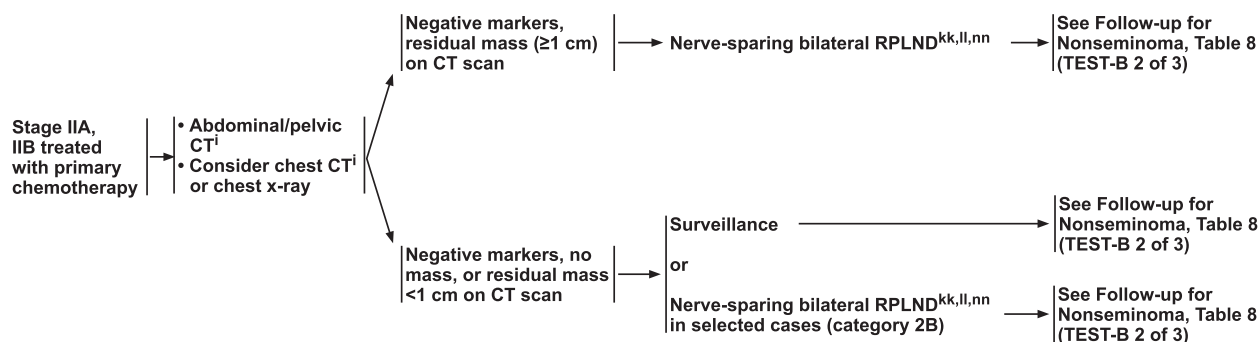
Sperm banking should be discussed with patients of reproductive age, if clinically indicated, before undergoing any therapeutic intervention that may compromise fertility.<sup>28–31</sup> If sperm banking is desired, it may be performed before orchiectomy in patients with risk factors for infertility (atrophic contralateral testicle, history of infertility), but certainly should be considered before subsequent therapy in patients who desire future fertility.

Further management is dictated by histology, stage, and whether the cancer is a pure seminoma or a non-seminoma (includes mixed GCTs that are partially comprised of seminoma and tumors that are histopathologically described as pure seminomas in patients with elevated serum AFP). Although it is rare, when a patient presents with: 1) markedly elevated beta-hCG or AFP levels; 2) a testicular mass and/or disease distribution typical for a testicular, retroperitoneal, or mediastinal GCT; or 3) a clinical scenario in which, due to the bulk, signs, or symptoms of disease, the risk of delaying systemic therapy outweighs the benefit of a tissue diagnosis, chemotherapy may be started immediately without waiting for a biopsy diagnosis or performing orchiectomy. Consolidative orchiectomy may be performed after completion of systemic therapy.

### Staging

Staging of testicular GCTs is based on determination of the extent of disease and assessment of postorchiectomy levels of serum tumor markers.<sup>12</sup> The tumor (T), node (N), and metastasis (M) staging system used by the AJCC is the internationally accepted standard for cancer staging and is a major factor influencing prognosis and treatment

## POSTCHEMOTHERAPY MANAGEMENT



<sup>i</sup> With contrast.

<sup>kk</sup> RPLND is recommended within 4 weeks of CT scan and 7–10 days of marker measurement.

<sup>ll</sup> See Principles of Surgery for Germ Cell Tumors (TEST-H\*).

<sup>nn</sup> Referral to high-volume centers should be considered for surgical resection of masses post-chemotherapy.

\*Available online, in these guidelines, at NCCN.org.

Version 2.2020, 11/20/19 © National Comprehensive Cancer Network, Inc. 2019. All rights reserved.  
The NCCN Guidelines® and this illustration may not be reproduced in any form without the express written permission of NCCN.

TEST-9

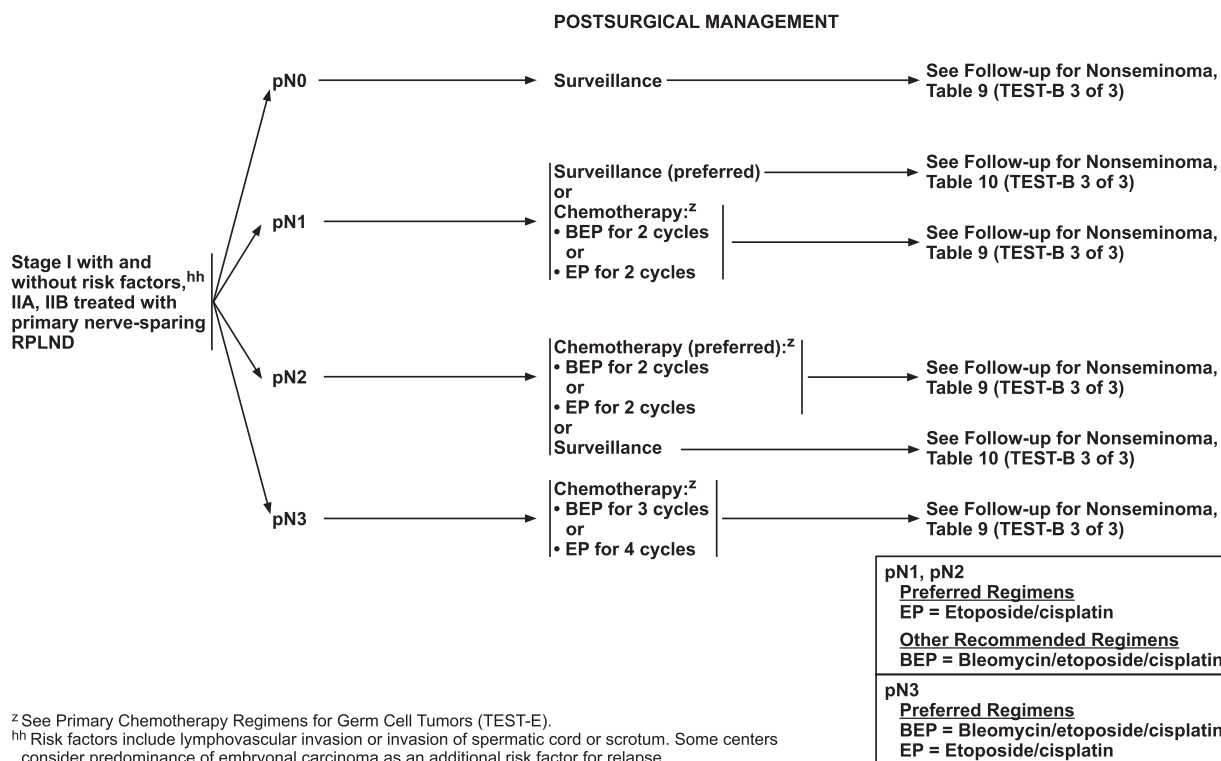
decisions. The AJCC TNM staging system incorporates serum tumor marker elevation as a distinct category (S), which is unique to this organ site. The extent of the primary tumor is classified after orchiectomy, and therefore pathologic (p) staging is assigned to the primary tumor (T).

The eighth edition of the *AJCC Cancer Staging Manual*<sup>12</sup> introduced invasion of the epididymis and hilar soft tissue as new pathologic criteria used for T classification of stage I testicular GCTs.<sup>32</sup> Due to the excellent clinical outcomes seen in testicular cancer, large-scale follow-up studies have historically used tumor relapse rather than tumor-specific survival to validate the relevance of pathologic parameters used for staging.<sup>12</sup> However, the association of hilar soft tissue and epididymal invasion with relapse of stage I disease has not been validated. Current data only support their association with having advanced-stage disease at diagnosis.<sup>33,34</sup> Therefore, the NCCN Panel believes that these factors should not be used for clinical decision-making in the management of these patients. Instead, the NCCN Guidelines recommend managing patients with stage I nonseminoma based on the presence or absence of lymphovascular invasion (LVI), invasion of the spermatic cord, or invasion of the scrotum, which are

factors known to be associated with an increased risk of relapse.<sup>35–43</sup>

Predominance of embryonal carcinoma has also been proposed as a prognostic indicator of relapse in stage I nonseminoma, with several studies showing that a high proportion of embryonal carcinoma in the primary tumor (>50%) is associated with an increased risk of relapse.<sup>37,44–51</sup> However, very few patients have a high volume of embryonal carcinoma without also having LVI, and the value of embryonal carcinoma predominance in predicting relapse in the absence of LVI is unclear.<sup>37,44,47,51</sup> Therefore, predominance of embryonal carcinoma is not used by the NCCN Guidelines to risk-stratify patients with stage I nonseminoma. Patients with stage I nonseminoma with a high volume of embryonal carcinoma and no evidence of LVI are neither high-risk nor low-risk and could be considered for adjuvant therapy.

The eighth edition of the *AJCC Cancer Staging Manual* also introduced changes to pathologic staging based on the type of spermatic cord involvement. Currently, continuous involvement of the spermatic cord soft tissue by the primary tumor is staged as pT3, whereas discontinuous spermatic cord involvement by invasion of lymphovascular spaces is now considered as a metastatic deposit (pM1).<sup>12</sup> This significant change results in



Version 2.2020, 11/20/19 © National Comprehensive Cancer Network, Inc. 2019. All rights reserved.  
 The NCCN Guidelines® and this illustration may not be reproduced in any form without the express written permission of NCCN.

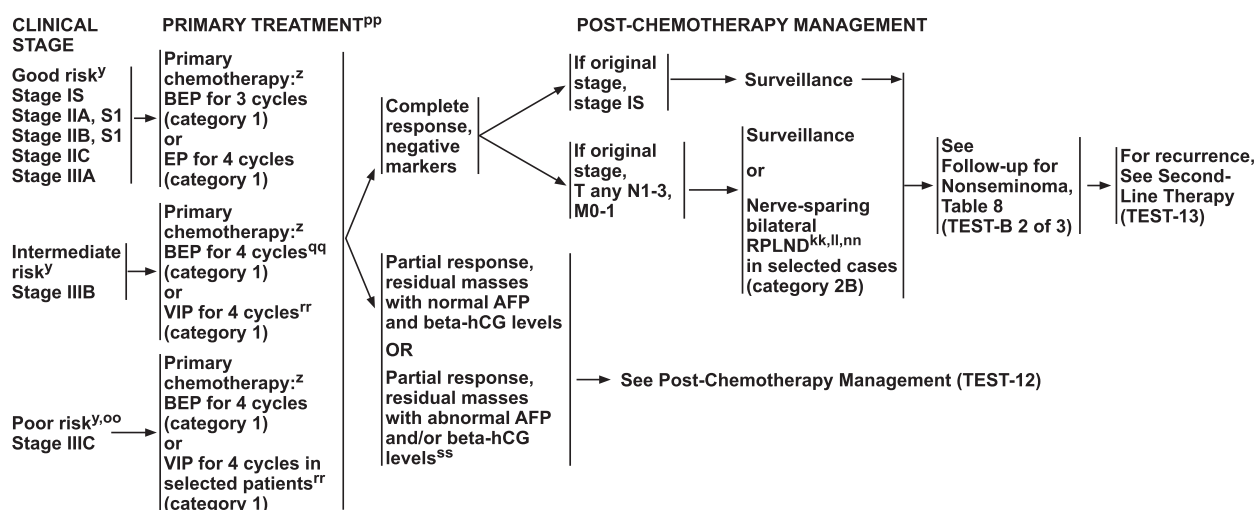
TEST-10

patients with discontinuous spermatic cord involvement being upstaged from high risk stage I to stage III disease independent of radiologic or serologic assessment, which the panel is concerned may lead to overtreatment. The evidence used to support this change is unclear; presently, there are no data showing differences in clinical outcomes between men with discontinuous spermatic cord involvement compared with men with continuous involvement. A recent retrospective analysis assessing the impact of different patterns of spermatic cord involvement on clinical stage and patient outcomes found no significant differences in either clinical stage at presentation or risk of recurrence based on type of spermatic cord involvement (continuous versus discontinuous).<sup>52</sup> Therefore, for management decisions, the panel recommends staging GCTs with discontinuous invasion of the spermatic cord as pT3 (high-risk stage I) and not as pM1 (stage III) as is recommended by the AJCC. If surveillance is elected as primary management, the pelvis should be included in the imaging due to a higher risk of pelvic relapses in these patients.

## Nonseminoma

Nonseminomatous GCTs include nonseminoma tumors, mixed seminoma/nonseminoma tumors, and

seminoma tumors in patients with elevated serum AFP levels. To assess for metastatic disease, CT scans of the chest, abdomen, and pelvis should be performed (see TEST-6, page 1531). Use of PET/CT scan is not clinically indicated for nonseminoma.<sup>53,54</sup> In select patients, brain MRI should also be performed; these patients include those with neurologic symptoms, postorchiectomy serum beta-hCG >5,000 IU/L or AFP >10,000 ng/mL, nonpulmonary visceral metastasis or extensive lung metastases. Elevated levels of serum beta-hCG, LDH, or AFP should be followed up with repeated tests. Repeated measurement of serum tumor markers is important because TNM staging is based on postorchiectomy values. In patients who had elevated serum tumor markers before orchiectomy, it is important to obtain the half-life kinetics of the tumor markers after orchiectomy if the markers are declining, because a slower-than-expected decline often indicates the presence of metastatic disease. The NCCN Panel emphasizes that mildly elevated, nonrising AFP levels may not indicate the presence of a GCT. Therefore, decisions to treat should not be based on AFP levels <20 ng/mL. Similarly, further workup should be considered before initiating treatment of mildly elevated beta-hCG (generally <20 IU/L).



**Preferred Regimens**  
 BEP = Bleomycin/etoposide/cisplatin  
 EP = Etoposide/cisplatin  
**Other Recommended Regimens**  
 VIP = Etoposide/ifosfamide/cisplatin

<sup>y</sup> See Risk Classification for Advanced Disease (TEST-D).

<sup>z</sup> See Primary Chemotherapy Regimens for Germ Cell Tumors (TEST-E).

<sup>kk</sup> RPLND is recommended within 4 weeks of CT scan and 7–10 days of marker measurement.

<sup>ll</sup> See Principles of Surgery for Germ Cell Tumors (TEST-H\*).

<sup>nn</sup> Referral to high-volume centers should be considered for surgical resection of masses post-chemotherapy.

\*Available online, in these guidelines, at NCCN.org.

<sup>oo</sup> Consider consultation with a high-volume center.

<sup>pp</sup> To assess response after treatment, CT with contrast of chest/abdomen/pelvis and any other sites of disease is recommended.

<sup>qq</sup> If intermediate risk is based on LDH 1.5–3 times the upper limit of normal, then BEP for 3 cycles can be considered.

<sup>rr</sup> Patients who may not tolerate bleomycin.

<sup>ss</sup> Recommend referral to a high-volume center.

Version 2.2020, 11/20/19 © National Comprehensive Cancer Network, Inc. 2019. All rights reserved. The NCCN Guidelines® and this illustration may not be reproduced in any form without the express written permission of NCCN.

TEST-11

Treatment options for clinical stage I disease after inguinal orchiectomy include surveillance, systemic therapy, and RPLND. Patients with clinical stage I pure teratoma and normal markers should receive either surveillance or RPLND. Stage II disease may be treated with systemic therapy or RPLND. Systemic therapy is preferred if serum tumor markers are elevated and/or if the enlarged lymph nodes are >3 cm in greatest dimension. RPLND is preferred as primary treatment of stage I or II tumors with transformed teratoma and should be considered for stage II tumors with teratoma predominance if serum tumor markers are normal. The major morbidity associated with bilateral RPLND is retrograde ejaculation, resulting in infertility. Nerve-sparing dissection techniques preserve antegrade ejaculation in 90% of cases.<sup>55</sup> Therefore, nerve-sparing RPLND is recommended. Limited data suggest increased frequency of aberrant recurrences with the use of minimally invasive laparoscopic or robotic approaches to RPLND. A recent study of recurrence patterns in patients after robotic RPLND found that recurrences were highly variable, were in unusual locations, and were associated with a high treatment burden.<sup>56</sup> Therefore, minimally invasive RPLND is not recommended as standard management at this time. Stage II and stage III

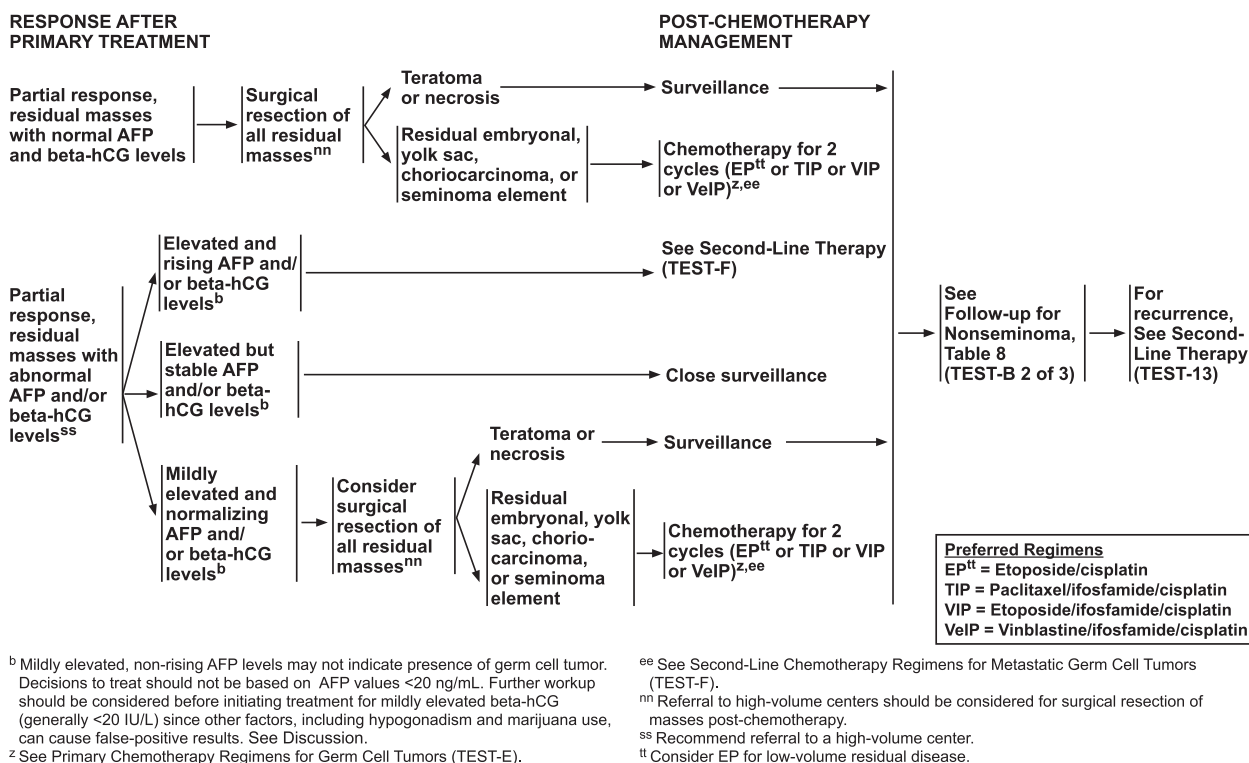
disease treated with systemic chemotherapy should be followed by surgical resection of any residual masses.

Patients with an extragonadal primary site, whether retroperitoneal or mediastinal, are managed similarly to patients with testicular GCTs regarding systemic therapies and management of residual masses.<sup>57</sup> However, due to their rarity, the NCCN Panel recommends that patients with extragonadal GCTs be referred to high-volume centers with experience in managing these tumors.

## Nonseminoma Stage I Without Risk Factors

### Primary Treatment of Nonseminoma Stage I Without Risk Factors

The panel recommends treating patients with stage I nonseminoma based on the presence or absence of risk factors known to be associated with an increased risk of relapse (LVI, invasion of the spermatic cord, or invasion of the scrotum).<sup>35–43</sup> However, regardless of risk factors, patients with stage I nonseminoma with normal post-orchietomy serum AFP and beta-hCG levels have 3 management options after orchiectomy: surveillance,<sup>40,47,58,59</sup> nerve-sparing RPLND,<sup>60</sup> or chemotherapy (1 cycle of bleomycin, etoposide and cisplatin [BEP])<sup>61,62</sup> as primary treatment (see TEST-7, page 1532, and TEST-E, page 1545). The



Version 2.2020, 11/20/19 © National Comprehensive Cancer Network, Inc. 2019. All rights reserved. The NCCN Guidelines® and this illustration may not be reproduced in any form without the express written permission of NCCN.

TEST-12

major difference in the management of low-risk and high-risk patients is that surveillance is preferred for patients with stage I nonseminoma without risk factors, whereas all 3 management options should be carefully considered when risk factors are present. The survival rates for stage I nonseminoma managed with surveillance, nerve-sparing RPLND, or 1 cycle of BEP chemotherapy exceed 98%. However, the high survival rate associated with surveillance depends on adherence to periodic follow-up examinations and subsequent chemotherapy for the 20%–30% of patients who experience relapse. Therefore, patients who choose surveillance should adhere to the follow-up schedule. When nerve-sparing RPLND is performed, it should be done within 4 weeks of a CT scan and within 7 to 10 days of repeat serum marker testing to ensure accurate pre-surgical staging.<sup>63</sup> Similarly, for patients electing 1 cycle of BEP, an abdominal/pelvic CT scan and chest X-ray or CT scan is recommended within 4 weeks before the initiation of chemotherapy to confirm staging, even if scans were done previously.

### Management of Nonseminoma Stage I Without Risk Factors After RPLND

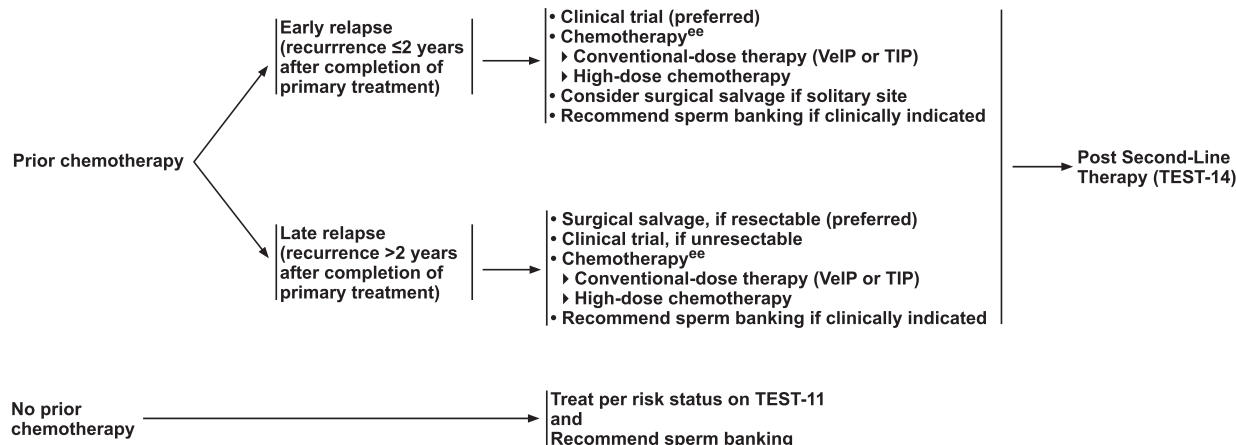
If the resected lymph nodes are negative for malignancy (pN0) after nerve-sparing RPLND, the patient should

undergo surveillance (see TEST-10, page 1535). For positive lymph nodes (pN1 to pN3), the decision whether to use chemotherapy is based on the degree of nodal involvement. Surveillance is the preferred option for patients with pN1 disease, and chemotherapy is the preferred option for patients with pN2 disease. However, chemotherapy is the only option for patients with pN3 disease. Recommended chemotherapy regimens include 2 cycles of either etoposide and cisplatin (EP; preferred) or BEP for patients with pN1 or pN2 disease<sup>64,65</sup> and 3 cycles of BEP or 4 cycles of EP (both preferred) for patients with pN3 disease.

### Follow-up for Nonseminoma Stage I Without Risk Factors

Although no single follow-up plan is applicable to all patients, the NCCN Panel has provided guidance for the follow-up of patients with nonseminoma for the first 5 years after the completion of therapy. These recommendations may be individualized and extended beyond 5 years at the discretion of the physician. The long-term follow-up for patients with stage I nonseminoma without risk factors includes history and physical examination, serum tumor marker assessment, abdominal/pelvic CT scan, and chest X-ray. In select



RECURRENCE<sup>uu</sup>SECOND-LINE THERAPY<sup>pp,vv</sup>**Preferred Regimens**

- High-dose chemotherapy<sup>ee</sup>
- TIP = Paclitaxel/ifosfamide/cisplatin
- VeIP = Vinblastine/ifosfamide/cisplatin

<sup>ee</sup> See Second-Line Chemotherapy Regimens for Metastatic Germ Cell Tumors (TEST-F).

<sup>pp</sup> To assess response after treatment, CT with contrast of chest/abdomen/pelvis and any other sites of disease is recommended.

<sup>uu</sup> It is preferred that patients with recurrent nonseminoma be treated at centers with expertise in the management of this disease.

<sup>vv</sup> Includes best supportive care and palliative care. See NCCN Guidelines for Palliative Care.<sup>†</sup>

<sup>†</sup>To view the most recent version of these guidelines, visit [NCCN.org](http://NCCN.org).

Version 2.2020, 11/20/19 © National Comprehensive Cancer Network, Inc. 2019. All rights reserved.  
The NCCN Guidelines® and this illustration may not be reproduced in any form without the express written permission of NCCN.

TEST-13

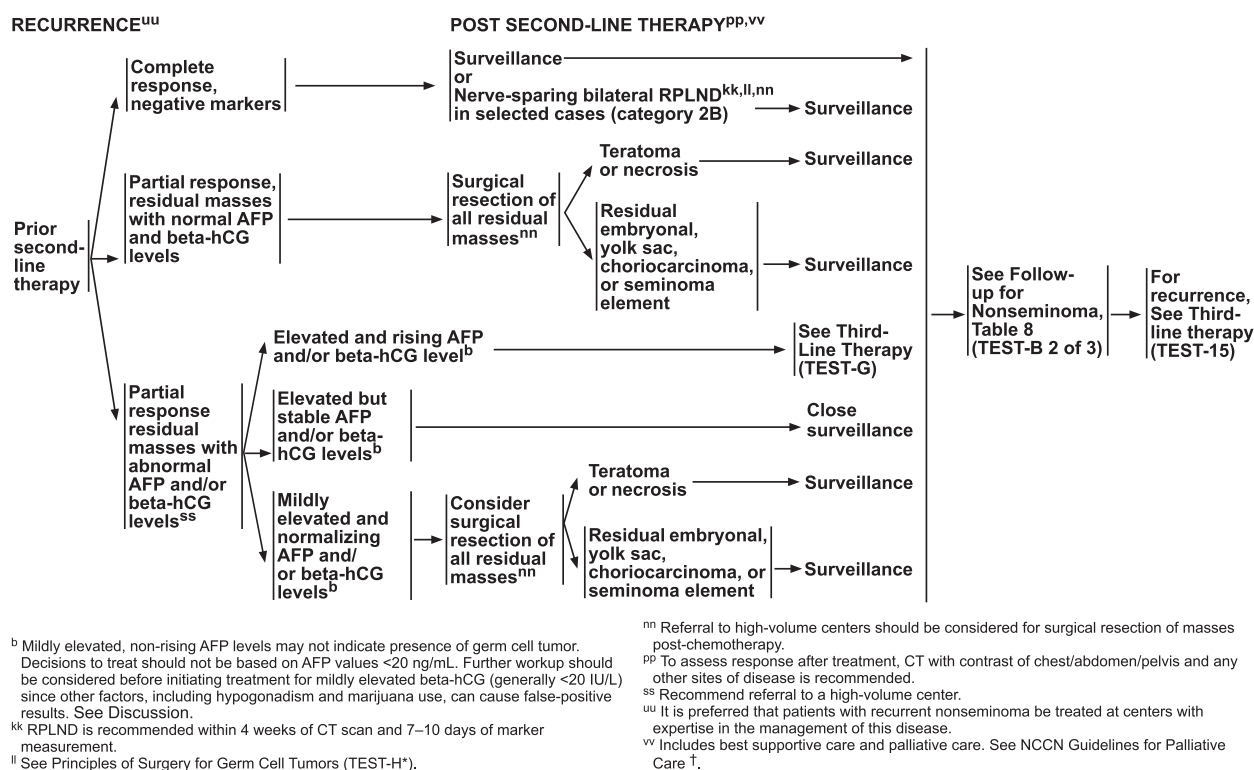
circumstances, an MRI can be considered to replace an abdominal/pelvic CT scan. The MRI protocol should include visualization of the retroperitoneal and pelvic nodes and should be performed in centers with experience in interpreting MRI results for testicular cancer. The same imaging modality (CT or MRI) should be used throughout surveillance. All imaging in this setting is performed with contrast. The frequency of these tests varies with the primary treatment modality received by the patient (see Tables 5 and 6 on TEST-B, page 1541). It should be noted that routine chest X-ray may have limited value for detecting relapse in stage I nonseminoma. In a recent retrospective study, a total of 76 relapses were detected among 561 patients with stage I nonseminoma managed using active surveillance after orchiectomy.<sup>66</sup> All relapses were detected with either rising serum tumor markers or abnormal routine follow-up CT scans; not a single relapse was detected using chest X-ray alone. Similar results have been reported in other studies, calling into question the value of chest X-rays in surveillance settings for stage I nonseminomatous GCTs.<sup>47,67,68</sup> The current schedule for routine chest X-ray in the follow-up of patients with stage I nonseminoma without risk factors is 2 chest X-rays in year 1 and 1 chest X-ray in years 2 through 5 in patients managed using surveillance. Chest

X-ray is not indicated in years 3, 4, and 5 for patients with stage I nonseminoma without risk factors treated with adjuvant BEP or primary RPLND.

## Nonseminoma Stage I With Risk Factors

### Primary Treatment of Nonseminoma Stage I With Risk Factors

Surveillance, adjuvant chemotherapy (1 cycle of BEP), or nerve-sparing RPLND are the recommended primary treatment options for patients with stage I nonseminoma with LVI, invasion of the spermatic cord, or invasion of the scrotum (see TEST-7, page 1532). In a prospective trial by SWENOTECA, patients with stage I nonseminoma with or without LVI received 1 course of adjuvant BEP.<sup>62</sup> The relapse rate at 5 years was 3.2% for patients with LVI and 1.6% for patients without LVI. Five-year overall survival (OS) was 100% in both groups.<sup>35</sup> The results after a median follow-up of 7.9 years confirmed the low relapse rate with 1 course of adjuvant BEP, especially in patients with LVI.<sup>35</sup> Several other studies using 2 cycles of BEP as primary treatment of stage I nonseminoma have similarly reported relapse-free survival rates >95%.<sup>59,65,69–72</sup> However, late consequences of cisplatin-based chemotherapy, such



\*Available online, in these guidelines, at NCCN.org. †To view the most recent version of these guidelines, visit NCCN.org.

Version 2.2020, 11/20/19 © National Comprehensive Cancer Network, Inc. 2019. All rights reserved. The NCCN Guidelines® and this illustration may not be reproduced in any form without the express written permission of NCCN.

TEST-14

as hearing damage and loss, cardiovascular conditions, hypertension, and neuropathy, have been reported during long-term follow-up.<sup>73–81</sup> Therefore, 1 cycle of BEP is recommended due to its lower toxicity. Surveillance is also a recommended primary treatment option for patients with stage I nonseminoma with risk factors. However, it should be noted that LVI is a significant predictor of relapse when orchiectomy is followed by surveillance alone.<sup>23</sup>

### Management of Nonseminoma Stage I With Risk Factors After RPLND

The management of patients with stage I nonseminoma with risk factors after primary RPLND is similar to that of patients with stage I nonseminoma without risk factors, as described previously.

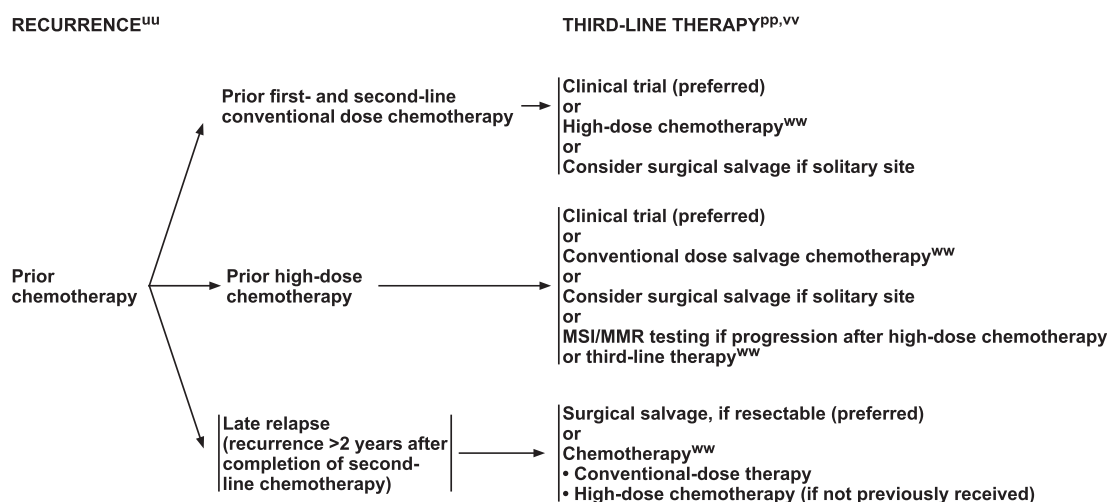
### Follow-up for Nonseminoma Stage I With Risk Factors

The long-term follow-up for patients with stage I nonseminoma with risk factors includes history and physical examination, serum tumor marker assessment, chest X-ray, and abdominal/pelvic CT scan. In select circumstances, an MRI can be considered to replace an abdominal/pelvic CT scan. All imaging in this setting is

performed with contrast. The frequency of these tests varies with the primary treatment modality received by the patient (see Tables 6 and 7, pages 1541 and 1542, respectively). Chest X-ray may be used for routine follow-up, but chest CT with contrast is preferred in patients with thoracic symptoms.

### Nonseminoma Stage IS

Patients with stage IS nonseminoma exhibit persistent elevation of serum tumor markers postorchiectomy but no radiographic evidence of disease. However, mildly elevated levels of AFP or beta-hCG after orchiectomy must be interpreted with caution. Mildly elevated, nonrising AFP levels (<20 ng/mL) may not indicate the presence of a GCT and should not be used to guide treatment decisions. In addition, hyperthyroidism, marijuana use, hypogonadism, and heterophile antibodies can result in significant elevations of beta-hCG.<sup>14–18</sup> Elevated beta-hCG due to metastatic disease typically rises steadily on serial measurements. In patients with mildly elevated but stable beta-hCG and no other evidence of metastatic disease, repeating the test using a different assay should be considered. Furthermore, many different conditions can result in an elevation of LDH, including many benign conditions. Therefore, patients should not be treated with



<sup>pp</sup> To assess response after treatment, CT with contrast of chest/abdomen/pelvis and any other sites of disease is recommended.

<sup>uu</sup> It is preferred that patients with recurrent nonseminoma be treated at centers with expertise in the management of this disease.

<sup>vv</sup> Includes best supportive care and palliative care. See NCCN Guidelines for Palliative Care.<sup>†</sup>

<sup>ww</sup> See Third-Line Chemotherapy Regimens for Metastatic Germ Cell Tumors (TEST-G).

<sup>†</sup>To view the most recent version of these guidelines, visit [NCCN.org](http://NCCN.org).

Version 2.2020, 11/20/19 © National Comprehensive Cancer Network, Inc. 2019. All rights reserved.  
The NCCN Guidelines® and this illustration may not be reproduced in any form without the express written permission of NCCN.

TEST-15

chemotherapy for systemic disease if the only evidence of systemic disease is an elevation of LDH.

### Primary Treatment of Nonseminoma Stage IS

The NCCN Panel recommends that patients with stage IS nonseminoma be treated with primary chemotherapy if the elevated marker is AFP or beta-hCG. For the purposes of this guideline, the panel assumes that patients with stage IS disease have markers in the S1 range. It would be extraordinarily rare for a patient to have an AFP >1,000 ng/mL or a beta-hCG >5,000 IU/L and yet have no evidence of metastatic disease on imaging studies. These guidelines cannot address every possible situation, and the management of those rare patients with T any, N0, M0, S2-3 disease should be individualized; consultation with a high-volume center is recommended. The vast majority of patients with stage IS have serum tumor markers in the S1 range, and they should receive primary chemotherapy for good-risk disease: either 3 cycles of BEP or 4 cycles of EP (both preferred; see TEST-11, page 1536, and TEST-E, page 1545). Both regimens are category 1 recommendations, and either is preferable to initial RPLND because these patients nearly always have disseminated disease.<sup>82,83</sup>

### Management of Nonseminoma Stage IS After Primary Treatment

The management of patients with stage IS nonseminoma after primary treatment with chemotherapy is described subsequently (see “Management of Good, Intermediate, and Poor-Risk Nonseminoma After Chemotherapy,” page 1544).

### Nonseminoma Stage IIA

#### Primary Treatment of Nonseminoma Stage IIA

Primary treatment of patients with stage IIA nonseminoma depends on postorchiectomy serum tumor marker levels (see TEST-8, page 1533). For patients with normal postorchiectomy levels of AFP and beta-hCG, the NCCN Panel recommends either nerve-sparing RPLND or chemotherapy with 3 cycles of BEP or 4 cycles of EP as primary treatment options (both BEP and EP are preferred regimens; see TEST-E, page 1545).<sup>84,85</sup> Chemotherapy is considered particularly appropriate if the patient has multifocal disease. For patients with stage IIA disease with persistently elevated AFP and/or beta-hCG levels, the NCCN Panel recommends primary chemotherapy with 3 cycles of BEP or 4 cycles of EP (both category 1; both preferred).<sup>60,86</sup> A bleomycin-free regimen should be considered in patients with reduced or

## FOLLOW-UP FOR NONSEMINOMA

No single follow-up plan is appropriate for all patients. The follow-up for nonseminoma tables are to provide guidance, and should be modified for the individual patient based on sites of disease, biology of disease, and length of time on treatment *and may be extended beyond 5 years at the discretion of the physician*. Reassessment of disease activity should be performed in patients with new or worsening signs or symptoms of disease, regardless of the time interval from previous studies. Further study is required to define optimal follow-up duration.

Table 5 Clinical Stage I without Risk Factors, NSGCT: Active Surveillance

	Year (at month intervals)				
	1	2	3	4	5
H&P and markers <sup>a</sup>	Every 2 mo	Every 3 mo	Every 4–6 mo	Every 6 mo	Annually
Abdominal ± Pelvic CT <sup>b,c</sup>	Every 4–6 mo	Every 6 mo	Annually	As clinically indicated	
Chest x-ray <sup>d</sup>	At mo 4 and 12	Annually	Annually	Annually	Annually

If Recurrence, see TEST-13.

Table 6 Clinical Stage I with Risk Factors, NSGCT: Active Surveillance

	Year (at month intervals)				
	1	2	3	4	5
H&P and markers <sup>a</sup>	Every 2 mo	Every 3 mo	Every 4–6 mo	Every 6 mo	Annually
Abdominal ± Pelvic CT <sup>b,c</sup>	Every 4 mo	Every 4–6 mo	Every 6 mo	Annually	As clinically indicated
Chest x-ray <sup>d</sup>	Every 4 mo	Every 4–6 mo	Every 6 mo	Annually	As clinically indicated

If Recurrence, see TEST-13.

<sup>a</sup> Testicular ultrasound for any equivocal exam.<sup>b</sup> With contrast.<sup>c</sup> In select circumstances, an MRI can be considered to replace an abdominal/pelvic CT. The MRI protocol should include all the nodes that need to be assessed. The same imaging modality (CT or MRI) should be used throughout surveillance. See Principles of Imaging (TEST-1<sup>o</sup>).<sup>d</sup> Chest x-ray may be used for routine follow-up, but chest CT with contrast is preferred in the presence of thoracic symptoms.

\*Available online, in these guidelines, at NCCN.org.

Version 2.2020, 11/20/19 © National Comprehensive Cancer Network, Inc. 2019. All rights reserved.  
The NCCN Guidelines® and this illustration may not be reproduced in any form without the express written permission of NCCN.TEST-B  
1 OF 3

borderline glomerular filtration rate (GFR), in patients over the age of 50, and in patients with chronic obstructive pulmonary disease or other lung disease resulting in reduced pulmonary function.

### Management of Nonseminoma Stage IIA After Primary Treatment

Treatment options after primary nerve-sparing RPLND include either surveillance or chemotherapy, depending on the number of positive lymph nodes identified (see TEST-10, page 1535). Because RPLND is likely a curative procedure in patients with pN0 disease, surveillance is recommended for this group. Surveillance is also the preferred option for patients with pN1 disease, although chemotherapy with 2 cycles of either EP or BEP can also be considered.<sup>60,87</sup> If chemotherapy is given, EP is the preferred regimen in this setting. The risk of relapse in patients with stage IIA nonseminoma with pN2 or pN3 disease after RPLND is >50%.<sup>60,88</sup> This risk is reduced to <1% with 2 cycles of adjuvant cisplatin-based chemotherapy.<sup>60,89,90</sup> Therefore, the NCCN Panel prefers 2 cycles of adjuvant chemotherapy with EP (preferred regimen) or BEP to surveillance for pN2 disease and recommends full-course chemotherapy (and not surveillance) for pN3 disease (either 3 cycles of BEP or 4 cycles of EP; both preferred).

Subsequent management after primary chemotherapy depends on the size of the residual mass on CT scan (see TEST-9, page 1534). Patients should thus undergo abdominal/pelvic CT scan with contrast within a month of completing chemotherapy; chest CT with contrast or chest X-ray may also be considered. If the residual mass is  $\geq 1$  cm after chemotherapy, nerve-sparing bilateral RPLND is recommended. A bilateral RPLND involves removal of lymphatic tissue between both ureters, spanning from the diaphragmatic crus to the bifurcation of the common iliac arteries. The rationale for this extended region of dissection is the greater likelihood of bilateral disease with greater tumor burden.<sup>91</sup> Referral to high-volume centers should be considered for surgical resection of masses post-chemotherapy. For patients with no residual mass or a residual mass <1 cm, surveillance is recommended. Nerve-sparing bilateral RPLND is a category 2B recommendation in this setting and may be performed in selected cases.

### Follow-up for Nonseminoma Stage IIA

The long-term follow-up for patients with stage IIA nonseminoma includes history and physical examination, serum tumor marker assessment, chest X-ray, and

## FOLLOW-UP FOR NONSEMINOMA

**Table 7. Clinical Stage IA/B NSGCT: Treated with 1 Cycle of Adjuvant BEP Chemotherapy or Primary RPLND**

	Year (at month intervals)				
	1	2	3	4	5
H&P and markers <sup>a</sup>	Every 3 mo	Every 3 mo	Every 6 mo	Every 6 mo	Annually
Abdominal ± Pelvic CT <sup>b,c</sup>	Annually	Annually <sup>e</sup>	—	—	—
Chest x-ray <sup>d</sup>	Every 6–12 mo	Annually	—	—	—

If Recurrence, see TEST-13.

**Table 8. Clinical Stage II–III NSGCT: Surveillance After Complete Response to Chemotherapy ± Post-chemotherapy RPLND<sup>f</sup>**

	Year (at month intervals)				
	1	2	3	4	5
H&P and marker <sup>a</sup>	Every 2 mo	Every 3 mo	Every 6 mo	Every 6 mo	Every 6 mo
Abdominal ± Pelvic CT <sup>b,c,g</sup>	Every 6 mo	Every 6–12 mo	Annually	As clinically indicated <sup>j</sup>	
Chest x-ray <sup>d,h</sup>	Every 6 mo	Every 6 mo	Annually <sup>i</sup>	Annually <sup>i</sup>	—

If Recurrence, see TEST-13.

<sup>a</sup> Testicular ultrasound for any equivocal exam.<sup>b</sup> With contrast.<sup>c</sup> In select circumstances, an MRI can be considered to replace an abdominal/pelvic CT. The MRI protocol should include all the nodes that need to be assessed. The same imaging modality (CT or MRI) should be used throughout surveillance. See Principles of Imaging (TEST-1<sup>a</sup>).<sup>d</sup> Chest x-ray may be used for routine follow-up, but chest CT with contrast is preferred in the presence of thoracic symptoms.<sup>f</sup> Patients who have an incomplete response to chemotherapy require more frequent imaging than is listed on this table.<sup>e</sup> Optional for patients treated with primary RPLND.<sup>g</sup> Patients with clinical stage II disease treated with chemotherapy who undergo post-chemotherapy RPLND and are found to have pN0 disease or pN1 pure teratoma need only 1 CT scan at postoperative month 3–4 and then as clinically indicated. See Discussion.<sup>h</sup> Chest CT with contrast if supradiaphragmatic disease at baseline.<sup>i</sup> Chest x-ray is optional at months 36 and 48.<sup>j</sup> For patients with unresectable residual masses or resected residual masses containing viable cancer.

\*Available online, in these guidelines, at NCCN.org.

Version 2.2020, 11/20/19 © National Comprehensive Cancer Network, Inc. 2019. All rights reserved. The NCCN Guidelines® and this illustration may not be reproduced in any form without the express written permission of NCCN.

TEST-B  
2 OF 3

abdominal/pelvic CT scan. In select circumstances, an MRI can be considered to replace an abdominal/pelvic CT. All imaging in this setting is performed with contrast. The frequency of these tests varies with the primary treatment modality and postsurgical management received by the patient (see Tables 8, 9, and 10 on TEST-B, pages 1542 and 1543). Chest X-ray may be used for routine follow-up, but chest CT with contrast is preferred in patients with thoracic symptoms.

## Nonseminoma Stage IIB

### Primary Treatment of Nonseminoma Stage IIB

Primary treatment of patients with stage IIB nonseminoma depends on postorchiectomy tumor marker levels and radiographic findings (see TEST-8, page 1533). When tumor marker levels are normal, the CT findings determine the proper course of treatment. If abnormal radiographic findings are limited to lymph node metastases within lymphatic drainage sites in the retroperitoneum (ie, the landing zone), patients may receive primary chemotherapy with either 3 cycles of BEP or 4 cycles of EP (both preferred; see TEST-E, page 1545) or primary nerve-sparing RPLND (reserved for highly selected cases). Both options of primary chemotherapy

or primary nerve-sparing RPLND are comparable in terms of outcome, but side effects and toxicity are different.<sup>85</sup> The reported relapse-free survival with either approach is close to 98%.<sup>88–90,92,93</sup> If metastatic disease (based on radiographic findings) is not confined to within the lymphatic drainage sites (ie, multifocal or symptomatic lymph node metastases with aberrant lymphatic drainage sites), primary chemotherapy (3 cycles of BEP or 4 cycles of EP; both preferred) is recommended. For patients with stage IIB nonseminoma with persistent marker elevation, the recommended treatment option is also primary chemotherapy with either 3 cycles of BEP or 4 cycles of EP (both category 1; both preferred). A bleomycin-free regimen should be considered in patients with reduced or borderline GFR and in patients over the age of 50.

### Management of Nonseminoma Stage IIB After Primary Treatment

The management of patients with stage IIB nonseminoma after primary treatment with either nerve-sparing RPLND or chemotherapy is similar to the postprimary management scheme outlined previously for patients with stage IIA nonseminoma (see



## FOLLOW-UP FOR NONSEMINOMA

**Table 9** Pathologic Stage IIA/B NSGCT: Post-Primary RPLND and Treated with Adjuvant Chemotherapy

	Year (at month intervals)				
	1	2	3	4	5
H&P and markers <sup>a</sup>	Every 6 mo	Every 6 mo	Annually	Annually	Annually
Abdominal/ Pelvic CT <sup>b,c,k</sup>	4 mo after RPLND	As clinically indicated			
Chest x-ray <sup>d</sup>	Every 6 mo	Annually	Annually	Annually	Annually

If Recurrence, see TEST-13.

**Table 10** Pathologic Stage IIA/B NSGCT: Post-Primary RPLND and **NOT** Treated with Adjuvant Chemotherapy<sup>l</sup>

	Year (at month intervals)				
	1	2	3	4	5
H&P and markers <sup>a</sup>	Every 2 mo	Every 3 mo	Every 4 mo	Every 6 mo	Annually
Abdominal/ Pelvic CT <sup>b,c</sup>	At 3–4 mo <sup>m</sup>	Annually	As clinically indicated		
Chest x-ray <sup>d</sup>	Every 2–4 mo	Every 3–6 mo	Annually	Annually	Annually

If Recurrence, see TEST-13.

<sup>a</sup> Testicular ultrasound for any equivocal exam.

<sup>b</sup> With contrast.

<sup>c</sup> In select circumstances, an MRI can be considered to replace an abdominal/pelvic CT. The MRI protocol should include all the nodes that need to be assessed. The same imaging modality (CT or MRI) should be used throughout surveillance. See Principles of Imaging (TEST-1\*).

<sup>d</sup> Chest x-ray may be used for routine follow-up, but chest CT with contrast is preferred in the presence of thoracic symptoms.

<sup>k</sup> Patients who undergo RPLND and are found to have pN0 disease or pN1 pure teratoma need only 1 CT scan at postoperative month 3–4 and then as clinically indicated. See Discussion.

<sup>l</sup> Patients with clinical stage IIA/IIB nonseminoma who undergo primary RPLND and are found to have pN0 disease (no tumor or teratoma, pathologic stage I) should revert to the surveillance schedule for low-risk NSGCT with the exception that only 1 CT scan is needed postoperatively around month 4 (Table 5).

<sup>m</sup> This schedule assumes a complete resection has taken place.

\*Available online, in these guidelines, at NCCN.org.

Version 2.2020, 11/20/19 © National Comprehensive Cancer Network, Inc. 2019. All rights reserved. The NCCN Guidelines® and this illustration may not be reproduced in any form without the express written permission of NCCN.

**TEST-B**  
3 OF 3

“Management of Nonseminoma Stage IIA After Primary Treatment,” page 1541).

### Follow-up for Nonseminoma Stage IIB

The long-term follow-up schedule for stage IIB nonseminoma patients is similar to the follow-up schedule outlined previously for patients with stage IIA nonseminoma and is dependent on the primary treatment modality and postsurgical management received by the patient (see “Follow-up for Nonseminoma Stage IIA,” page 1541, and TEST-B, pages 1541–1543).

### Advanced Metastatic Nonseminoma

The primary chemotherapy options for patients with advanced metastatic nonseminoma are based on the International Germ Cell Cancer Consensus Group (IGCCCG) risk classification, which categorizes patients as good, intermediate, or poor risk based on identification of clinically independent prognostic features such as extent of disease and postorchiectomy levels of serum tumor markers (see TEST-D, page 1544).<sup>94</sup> When determining a patient’s risk classification, the relevant serum tumor marker value is the value on day 1 of cycle 1 of first-line chemotherapy.

### Primary Treatment of Good-Risk Nonseminoma

The IGCCCG good-risk group includes patients with stages IS, IIA (S1), IIB (S1), IIC, and IIIA disease (see TEST-11, page 1536). Treatment of good-risk disease is designed to limit toxicity while maintaining maximal efficacy. Presently, 2 regimens are recommended by the NCCN Panel: 3 cycles of BEP<sup>95–97</sup> or 4 cycles of EP<sup>96–98</sup> (both category 1 preferred regimens; see TEST-E, page 1545). Although both regimens are well tolerated and cure approximately 90% of patients with good-risk disease,<sup>96,99</sup> 4 cycles of EP should be considered in patients with reduced or borderline GFR and in patients over the age of 50.

### Primary Treatment of Intermediate-Risk (Stage IIIB) Nonseminoma

For patients with intermediate-risk disease, the cure rate is approximately 70% with the standard chemotherapy regimen of 4 cycles of BEP.<sup>100,101</sup> Therefore, the NCCN Panel recommends 4 cycles of BEP (preferred), or 4 cycles of etoposide, ifosfamide, and cisplatin (VIP)<sup>100,102</sup> for patients who may not tolerate bleomycin, for the treatment of intermediate-risk (stage IIIB) nonseminoma. Both regimens are category 1 recommendations. However, if intermediate-risk status is based

**RISK CLASSIFICATION FOR ADVANCED DISEASE  
(post-orchietomy)<sup>a</sup>**

Risk Status	Nonseminoma	Seminoma
Good Risk	Testicular or retroperitoneal primary tumor <sup>b</sup> and No nonpulmonary visceral metastases and <u>Post-orchietomy markers</u> - all of: AFP < 1,000 ng/mL hCG < 5,000 iu/L LDH < 1.5 x upper limit of normal	Any primary site and No nonpulmonary visceral metastases and Normal AFP Any hCG Any LDH
Intermediate Risk	Testicular or retroperitoneal primary tumor <sup>b</sup> and No nonpulmonary visceral metastases and <u>Post-orchietomy markers</u> - any of: AFP 1,000–10,000 ng/mL hCG 5,000–50,000 iu/L LDH 1.5–10 x upper limit of normal	Any primary site and Nonpulmonary visceral metastases and Normal AFP Any hCG Any LDH
Poor Risk	Mediastinal primary tumor <sup>b</sup> or Nonpulmonary visceral metastases or <u>Post-orchietomy markers</u> - any of: AFP > 10,000 ng/mL hCG > 50,000 iu/L LDH > 10 x upper limit of normal	No patients classified as poor prognosis

Source: Figure 4 from the International Germ Cell Cancer Collaborative Group: International Germ Cell Consensus Classification: A Prognostic Factor-Based Staging System for Metastatic Germ Cell Cancers. *J Clin Oncol* 1997;15(2):594-603. Reprinted with permission of the American Society of Clinical Oncology.

<sup>a</sup> Markers used for risk classification are post-orchietomy.

<sup>b</sup> Referral to a high-volume center is recommended for patients with extragonadal germ cell tumors. See Discussion.

Version 2.2020, 11/20/19 © National Comprehensive Cancer Network, Inc. 2019. All rights reserved.  
The NCCN Guidelines® and this illustration may not be reproduced in any form without the express written permission of NCCN.

TEST-D

solely on LDH levels 1.5 to 3 times the upper limit of normal, then 3 cycles of BEP can be considered.

### **Primary Treatment of Poor-Risk (Stage IIIC) Nonseminoma**

The standard chemotherapy regimen for poor-risk disease is 4 cycles of BEP (preferred). Alternatively, 4 cycles of VIP can be used to treat patients who may not tolerate bleomycin (see TEST-E, above).<sup>102</sup> Both regimens are category 1 recommendations. However, fewer than 50% of patients with poor-risk nonseminoma experience a durable complete response to 4 cycles of BEP, and at least 30% die of their disease.<sup>94,103</sup> Therefore, consultation with a high-volume center should be considered for the management of these patients.<sup>99</sup>

### **Management of Good-, Intermediate-, and Poor-Risk Nonseminoma After Chemotherapy**

At the conclusion of primary chemotherapy, chest/abdominal/pelvic CT scan with contrast and measurement of serum tumor marker levels are indicated to assess treatment response. If a complete response to chemotherapy is found using radiographic imaging and the tumor marker levels are normal, the NCCN Panel recommends surveillance (see TEST-11, page 1536).

Nerve-sparing bilateral RPLND can be considered in select cases for patients who had retroperitoneal lymphadenopathy before chemotherapy (category 2B).<sup>104</sup> RPLND is recommended within 4 weeks of the CT scan and 7 to 10 days of marker measurement. Referral to high-volume centers should be considered for surgical resection of residual masses after chemotherapy.

If there is a partial radiographic response to chemotherapy (as indicated by the presence of residual masses) and tumor marker levels are normal, then surgical resection of all residual masses is recommended (see TEST-12, page 1537).<sup>105–108</sup> As previously stated, referral to high-volume centers should be considered for surgical resection of masses postchemotherapy. If only necrotic debris or teratoma is present in the resected tissue, the patient should be put under surveillance. If embryonal, yolk sac, choriocarcinoma, or seminoma elements are found in the residual mass, then 2 cycles of chemotherapy with EP; paclitaxel, ifosfamide, and cisplatin (TIP); VIP; or vinblastine, ifosfamide, and cisplatin (VeIP) should be administered. All regimens are preferred in this setting; however, EP should be reserved for patients with low-volume residual disease.

Further management for patients who experience a partial radiographic response to chemotherapy (residual

## PRIMARY CHEMOTHERAPY REGIMENS FOR GERM CELL TUMORS

**Preferred Regimens**• **BEP**

Etoposide 100 mg/m<sup>2</sup> IV on Days 1–5  
 Cisplatin 20 mg/m<sup>2</sup> IV on Days 1–5  
 Bleomycin 30 units IV weekly on Days 1, 8, and 15 or Days 2, 9, and 16  
 Repeat every 21 days<sup>1</sup>

• **EP**

(Option only for good-risk patients [see TEST-D], patients with pathologic stage II disease, and patients with viable germ cell tumor at surgery following first-line chemotherapy)  
 Etoposide 100 mg/m<sup>2</sup> IV on Days 1–5  
 Cisplatin 20 mg/m<sup>2</sup> IV on Days 1–5  
 Repeat every 21 days<sup>2</sup>

**Other Recommended Regimens**• **VIP<sup>3</sup>**

(Option only for intermediate or poor-risk patients or patients with viable germ cell tumor at surgery following first-line chemotherapy [See TEST-5 and TEST-11])  
 Etoposide 75 mg/m<sup>2</sup> IV on Days 1–5  
 Ifosfamide 1200 mg/m<sup>2</sup> on Days 1–5 with mesna protection  
 Cisplatin 20 mg/m<sup>2</sup> IV on Days 1–5  
 Repeat every 21 days<sup>4</sup>

<sup>1</sup> Saxman SB, Finch D, Gonin R, Einhorn LH. Long-term follow-up of a phase III study of three versus four cycles of bleomycin, etoposide, and cisplatin in favorable-prognosis germ-cell tumors: The Indiana University Experience. J Clin Oncol 1998;16:702-706.

<sup>2</sup> Xiao H, Mazumdar M, Bajorin DF, et al. Long-term follow-up of patients with good-risk germ cell tumors treated with etoposide and cisplatin. J Clin Oncol 1997;15:2553-2558.

<sup>3</sup> VIP: This regimen is high risk for febrile neutropenia and granulocyte colony-stimulating factors (G-CSFs) should be used (See NCCN Guidelines for Hematopoietic Growth Factors<sup>†</sup>).

<sup>4</sup> Nichols CR, Catalano PJ, Crawford ED, et al. Randomized comparison of cisplatin and etoposide and either bleomycin or ifosfamide in treatment of advanced disseminated germ cell tumors: An Eastern Cooperative Oncology Group, Southwest Oncology Group, and Cancer and Leukemia Group B Study. J Clin Oncol 1998;16:1287-1293.

<sup>†</sup>To view the most recent version of these guidelines, visit NCCN.org.

Version 2.2020, 11/20/19 © National Comprehensive Cancer Network, Inc. 2019. All rights reserved.  
 The NCCN Guidelines® and this illustration may not be reproduced in any form without the express written permission of NCCN.

TEST-E

masses) with abnormal tumor marker levels is guided by the kinetics of the tumor markers (see TEST-12, page 1537). If tumor marker levels are elevated and persistently rising, the NCCN Panel recommends a full course of second-line chemotherapy (see TEST-F, page 1546, and “Second-Line Therapy,” next column). Patients with elevated but stable marker levels should be closely surveilled. Patients with mildly elevated and normalizing markers should be considered for surgical resection of residual masses with subsequent postsurgical management as discussed previously. The panel recommends referral to a high-volume center for the management of patients with a partial response to primary chemotherapy and abnormal marker levels.

**Follow-up for Good-, Intermediate-, and Poor-Risk Nonseminoma**

The long-term follow-up for patients with good-, intermediate-, and poor-risk nonseminoma after chemotherapy (with or without postchemotherapy RPLND) includes history and physical examination, serum tumor marker assessment, chest X-ray, and abdominal/pelvic CT scan. The frequency of these tests are outlined in Table 8 on TEST-B (page 1542). Patients who have an incomplete response to chemotherapy require more

frequent imaging than is outlined in the table. Patients who undergo RPLND and are found to have pN0 disease or pN1 pure teratoma need only 1 CT scan at post-operative month 3 or 4 and then as clinically indicated. In select circumstances, an MRI can be considered to replace an abdominal/pelvic CT. All imaging in this setting is performed with contrast. Chest X-ray may be used for routine follow-up, but chest CT with contrast is preferred in patients with thoracic symptoms.

**Second-Line and Subsequent Therapy for Metastatic Germ Cell Tumors****Second-Line Therapy**

Patients with disease relapse after first-line therapy or those who do not experience a durable complete response to first-line therapy should receive second-line therapy. Patients with recurrent disease who have not been treated with prior chemotherapy should be managed per their risk status, as described in the preceding sections. The panel prefers that patients with recurrent nonseminoma be treated at centers with expertise in the management of this disease. Second-line therapy options for patients with early relapses (within 2 years of the completion of primary therapy) include enrollment in a

## SECOND-LINE CHEMOTHERAPY REGIMENS FOR METASTATIC GERM CELL TUMORS

Conventional-Dose Chemotherapy RegimensPreferred Regimens• TIP<sup>1</sup>

Paclitaxel 250 mg/m<sup>2</sup> IV on Day 1  
 Ifosfamide 1500 mg/m<sup>2</sup> IV on Days 2–5 with mesna protection  
 Cisplatin 25 mg/m<sup>2</sup> IV on Days 2–5  
 Repeat every 21 days<sup>2</sup>

• VeIP<sup>1</sup>

Vinblastine 0.11 mg/kg IV Push on Days 1–2  
 Ifosfamide 1200 mg/m<sup>2</sup> IV on Days 1–5 with mesna protection  
 Cisplatin 20 mg/m<sup>2</sup> IV on Days 1–5  
 Repeat every 21 days<sup>3</sup>

High-Dose Chemotherapy RegimensPreferred Regimens

## • Carboplatin/etoposide

Carboplatin 700 mg/m<sup>2</sup> (body surface area) IV  
 Etoposide 750 mg/m<sup>2</sup> IV  
 Administer 5, 4, and 3 days before peripheral blood stem cell infusion for 2 cycles<sup>4</sup>

## • Paclitaxel/ifosfamide/carboplatin/etoposide

Paclitaxel 200 mg/m<sup>2</sup> IV over 24 hours on Day 1  
 Ifosfamide 2000 mg/m<sup>2</sup> over 4 hours with mesna protection on Days 2–4  
 Repeat every 14 days for 2 cycles followed by  
 Carboplatin AUC 7–8 IV over 60 minutes on Days 1–3  
 Etoposide 400 mg/m<sup>2</sup> IV on Days 1–3  
 Administer with peripheral blood stem cell support at 14- to 21-day intervals for 3 cycles<sup>5</sup>

<sup>1</sup>TIP, VeIP: These regimens are high risk for febrile neutropenia and G-CSFs should be used (See NCCN Guidelines for Hematopoietic Growth Factors<sup>†</sup>).

<sup>2</sup>Kondagunta GV, Bacik J, Donadio A, et al. Combination of paclitaxel, ifosfamide, and cisplatin is an effective second-line therapy for patients with relapsed testicular germ cell tumors. *J Clin Oncol* 2005;23:6549-6555.

<sup>3</sup>Loehrer PJ Sr, Lauer R, Roth BJ, et al. Salvage therapy in recurrent germ cell cancer: ifosfamide and cisplatin plus either vinblastine or etoposide. *Ann Intern Med* 1988;109:540-546.

<sup>4</sup>Einhorn LH, Williams SD, Chamness A, et al. High-dose chemotherapy and stem-cell rescue for metastatic germ-cell tumors. *N Engl J Med* 2007;357:340-348.

<sup>5</sup>Feldman DR, Sheinfeld J, Bajorin DF et al. TI-CE high-dose chemotherapy for patients with previously treated germ cell tumors: results and prognostic factor analysis. *J Clin Oncol* 2010;28:1706-1713.

<sup>†</sup>To view the most recent version of these guidelines, visit NCCN.org.

Version 2.2020, 11/20/19 © National Comprehensive Cancer Network, Inc. 2019. All rights reserved.  
 The NCCN Guidelines® and this illustration may not be reproduced in any form without the express written permission of NCCN.

TEST-F

clinical trial (preferred), conventional-dose chemotherapy, or high-dose chemotherapy (see TEST-13, page 1538). If chemotherapy is given, both conventional-dose and high-dose regimens are preferred in this setting. The conventional-dose regimens are TIP or VeIP.<sup>109–112</sup> The high-dose regimens include high-dose carboplatin plus etoposide followed by autologous stem cell transplant,<sup>113</sup> or paclitaxel plus ifosfamide followed by high-dose carboplatin plus etoposide with stem cell support (see TEST-F, page 1546).<sup>114</sup> Alternatively, surgical salvage may be considered if the recurrent mass is in a solitary resectable site.<sup>115</sup> Late relapses (>2 years after completion of primary therapy) occur in 2%–3% of testicular cancer survivors.<sup>116,117</sup> The NCCN Panel prefers surgical salvage for these patients if the recurrent mass is resectable.<sup>115</sup> If it is unresectable, chemotherapy (conventional or high dose) is the preferred option. Clinical trial enrollment is also an option for patients with unresectable late relapse.

Because it is not currently known whether high-dose chemotherapy is better than conventional-dose chemotherapy in the second-line setting for patients with relapsed disease, the NCCN Panel recommends clinical trial enrollment for these patients. An ongoing, randomized, international phase III trial (TIGER) will compare second-line conventional-dose chemotherapy

with high-dose chemotherapy in patients with relapsed GCTs.<sup>118</sup> The foundation of the TIGER trial was formed based on the results of a large retrospective analysis by Lorch et al<sup>119</sup> which showed the superiority of carboplatin-based high-dose chemotherapy compared with cisplatin-based conventional-dose chemotherapy with respect to 2-year progression-free survival (50% vs 28%;  $P<.001$ ) and 5-year OS (53% vs 41%,  $P<.001$ ).<sup>120</sup> The TIGER trial will randomize patients with unequivocal disease progression after cisplatin-based primary chemotherapy to receive conventional-dose TIP or high-dose paclitaxel plus ifosfamide followed by high-dose carboplatin plus etoposide with stem cell support. OS is the primary endpoint. Secondary endpoints include progression-free survival, response rate, toxicity, quality of life, and biologic correlates.<sup>118,120</sup> This trial is currently recruiting patients, and participation is highly encouraged (ClinicalTrials.gov identifier: NCT02375204).

### Management of Metastatic Germ Cell Tumors After Second-Line Therapy

To assess response after second-line therapy, a CT scan with contrast of the chest, abdomen, pelvis, and any other sites of disease is recommended. Levels of serum

### THIRD-LINE CHEMOTHERAPY REGIMENS FOR METASTATIC GERM CELL TUMORS<sup>a</sup> High-Dose Chemotherapy NOT Previously Received

#### Preferred Regimens (High-Dose Chemotherapy)

- Carboplatin/etoposide  
Carboplatin 700 mg/m<sup>2</sup> (body surface area) IV  
Etoposide 750 mg/m<sup>2</sup> IV  
Administered 5, 4, and 3 days before peripheral blood stem cell infusion for 2 cycles<sup>1</sup>
- Paclitaxel/ifosfamide/carboplatin/etoposide  
Paclitaxel 200 mg/m<sup>2</sup> IV over 24 hours on Day 1  
Ifosfamide 2000 mg/m<sup>2</sup> over 4 hours with mesna protection on Days 2–4  
Repeat every 14 days for 2 cycles followed by  
Carboplatin AUC 7–8 IV over 60 minutes on Days 1–3  
Etoposide 400 mg/m<sup>2</sup> IV on Days 1–3  
Administered with peripheral blood stem cell support at 14- to 21-day intervals for 3 cycles<sup>2</sup>

#### Other Recommended Regimens

- Gemcitabine/paclitaxel/oxaliplatin<sup>3</sup>  
Gemcitabine 800 mg/m<sup>2</sup> IV over 30 minutes on Days 1 and 8  
Paclitaxel 80 mg/m<sup>2</sup> IV over 60 minutes on Days 1 and 8  
Oxaliplatin 130 mg/m<sup>2</sup> IV over 2 hours on Day 1  
Administered on a 21-day cycle for 8 cycles
- Gemcitabine/oxaliplatin<sup>4-6</sup>  
Gemcitabine 1000–1250 mg/m<sup>2</sup> IV over 30 minutes on Days 1 and 8  
followed by  
Oxaliplatin 130 mg/m<sup>2</sup> IV over 2 hours on Day 1  
Administered on a 21-day cycle until disease progression or unacceptable toxicity
- Gemcitabine/paclitaxel<sup>7,8</sup>  
Gemcitabine 1000 mg/m<sup>2</sup> IV over 30 minutes on Days 1, 8, and 15  
Paclitaxel 100 mg/m<sup>2</sup> IV over 60 minutes on Days 1, 8, and 15  
Administered on a 28-day cycle for 6 cycles
- Etoposide (oral)<sup>9</sup>  
Etoposide 50–100 mg PO daily on Days 1–21  
Administered on a 28-day cycle until disease progression or unacceptable toxicity

#### Useful in Certain Circumstances

- Pembrolizumab (for MSI-H/dMMR tumors)<sup>10,11</sup>  
Pembrolizumab 200 mg IV over 30 minutes on Day 1  
Administered on a 21-day cycle until disease progression or unacceptable toxicity

<sup>a</sup> If Velp or TIP received as second-line therapy, high-dose chemotherapy is the preferred third-line option.

Version 2.2020, 11/20/19 © National Comprehensive Cancer Network, Inc. 2019. All rights reserved.  
The NCCN Guidelines® and this illustration may not be reproduced in any form without the express written permission of NCCN.

TEST-G  
1 OF 3

tumor markers should also be measured. Patients with a complete response to second-line therapy with normal marker levels should be put under surveillance. Alternatively, select patients may receive nerve-sparing bilateral RPLND (category 2B), followed by surveillance. For patients with a partial response to second-line therapy (as indicated by residual masses on CT scan) and normal marker levels, surgical resection of all residual masses is recommended followed by surveillance. Patients with a partial response to second-line therapy (residual masses) and abnormal marker levels should be managed according to the kinetics of the tumor markers (see TEST-14, page 1539). If tumor marker levels are elevated and persistently rising, the panel recommends third-line therapy (see TEST-G, previous page and above, and “Third-Line Therapy,” subsequent section). Patients with elevated but stable tumor marker levels should be closely surveilled. Patients with mildly elevated and normalizing markers should be considered for surgical resection of residual masses followed by surveillance.

### Third-Line Therapy

Participation in a clinical trial is the preferred treatment option for patients who experience relapse after

first- and second-line therapy (see TEST-15, page 1540). Alternatively, patients previously treated with conventional-dose chemotherapy can receive high-dose regimens or be considered for surgical salvage if the recurrent mass is in a solitary resectable site. Alternative options for patients previously treated with high-dose regimens include conventional-dose salvage chemotherapy, surgical salvage (if solitary site), and microsatellite instability/mismatch repair (MSI/MMR) testing (if disease progresses after high-dose chemotherapy or third-line therapy). The preferred treatment option for patients who experience a late relapse (>2 years after completion of second-line therapy) is surgical salvage, if the recurrent mass is resectable. Conventional-dose or high-dose chemotherapy (if not previously received), are also options for patients with late relapse.

To maintain optimal efficacy and limit treatment-related toxicities, the chemotherapy regimens previously received by the patient should be considered when deciding on third-line therapy options. High-dose chemotherapy is the preferred third-line option if it has not been previously received (see TEST-G, page 1547). If high-dose chemotherapy was previously received by the patient, then palliative chemotherapy is the preferred third-line treatment option. Additionally, the panel



### THIRD-LINE CHEMOTHERAPY REGIMENS FOR METASTATIC GERM CELL TUMORS<sup>a</sup> High-Dose Chemotherapy Previously Received

#### Preferred Regimens

- Gemcitabine/paclitaxel/oxaliplatin<sup>3</sup>  
Gemcitabine 800 mg/m<sup>2</sup> IV over 30 minutes on Days 1 and 8  
Paclitaxel 80 mg/m<sup>2</sup> IV over 60 minutes on Days 1 and 8  
Oxaliplatin 130 mg/m<sup>2</sup> IV over 2 hours on Day 1  
Administered on a 21-day cycle for 8 cycles
- Gemcitabine/oxaliplatin<sup>4,6</sup>  
Gemcitabine 1000–1250 mg/m<sup>2</sup> IV over 30 minutes on Days 1 and 8  
followed by  
Oxaliplatin 130 mg/m<sup>2</sup> IV over 2 hours on Day 1  
Administered on a 21-day cycle until disease progression or unacceptable toxicity
- Gemcitabine/paclitaxel<sup>7,8</sup>  
Gemcitabine 1000 mg/m<sup>2</sup> IV over 30 minutes on Days 1, 8, and 15  
Paclitaxel 100 mg/m<sup>2</sup> IV over 60 minutes on Days 1, 8, and 15  
Administered on a 28-day cycle for 6 cycles
- Etoposide (oral)<sup>9</sup>  
Etoposide 50–100 mg PO daily on Days 1–21  
Administered on a 28-day cycle until disease progression or unacceptable toxicity

#### Useful in Certain Circumstances

- Pembrolizumab (for MSI-H/dMMR tumors)<sup>10,11</sup>  
Pembrolizumab 200 mg IV over 30 minutes on Day 1  
Administered on a 21-day cycle until disease progression or unacceptable toxicity

<sup>a</sup>If VeIP or TIP received as second-line therapy, high-dose chemotherapy is the preferred third-line option.

Version 2.2020, 11/20/19 © National Comprehensive Cancer Network, Inc. 2019. All rights reserved.  
The NCCN Guidelines® and this illustration may not be reproduced in any form without the express written permission of NCCN.

TEST-G  
2 OF 3

considers pembrolizumab immunotherapy to be useful in certain circumstances (ie, in patients with MSI-high/deficient MMR [MSI-H/dMMR] tumors).

The recommended third-line palliative chemotherapy options for patients with intensively pretreated, cisplatin-resistant, or refractory GCTs are combinations of gemcitabine with paclitaxel and/or oxaliplatin,<sup>121–127</sup> or oral etoposide.<sup>128</sup> The recommendation for gemcitabine and oxaliplatin (GEMOX) is based on data from phase II studies investigating the efficacy and toxicity of GEMOX in patients with relapsed or cisplatin-resistant GCTs.<sup>122,124,126</sup> These studies showed that GEMOX is safe for patients with cisplatin-resistant testicular GCTs and may offer a chance of long-term survival.<sup>122,124,126</sup> Gemcitabine and paclitaxel is another option that has shown promising results in a phase II study.<sup>123</sup> Follow-up results showed long-term disease-free survival in patients who showed progression after high-dose chemotherapy and who had not received prior paclitaxel or gemcitabine.<sup>125</sup> A phase II study of patients with treatment-resistant GCTs also found the combination of gemcitabine, oxaliplatin, and paclitaxel to be effective with acceptable toxicity.<sup>121</sup> The overall response rate was 51% with 5% of patients experiencing a complete response. A second study reported similar results.<sup>127</sup> Additionally,

high-dose single-agent oral etoposide was shown to be effective in a phase II study involving patients who had previous treatment with cisplatin/etoposide combination regimens.<sup>128</sup>

Pembrolizumab, an anti-PD-1 antibody, was approved by the FDA for the treatment of patients with unresectable or metastatic MSI-H/dMMR solid tumors that have progressed after previous treatment and who have no satisfactory alternative treatment options.<sup>129</sup> This first-ever tissue- and site-agnostic indication was based on data from phase II clinical trials that demonstrated the efficacy of pembrolizumab in MSI-H/dMMR solid tumors.<sup>130,131</sup> In the only trial (phase II) investigating the efficacy of immunotherapy in testicular cancer, 12 patients with nonseminoma GCTs that progressed after first-line cisplatin-based chemotherapy and at least 1 salvage regimen (high-dose or conventional-dose chemotherapy) were treated with pembrolizumab.<sup>132</sup> Two patients experienced stable disease for 28 and 19 weeks, respectively, but no partial or complete responses were seen. The study showed 6 grade-3 adverse events, but no immune-related adverse events were reported. Therefore, pembrolizumab was well tolerated but appears to have limited single-agent activity in refractory GCTs. However, larger phase II and phase III trials of

### THIRD-LINE CHEMOTHERAPY REGIMENS FOR METASTATIC GERM CELL TUMORS REFERENCES

- <sup>1</sup> Einhorn LH, Williams SD, Chamness A, et al. High-dose chemotherapy and stem-cell rescue for metastatic germ-cell tumors. *N Engl J Med* 2007;357:340-348.
- <sup>2</sup> Feldman DR, Sheinfeld J, Bajorin DF et al. TI-CE high-dose chemotherapy for patients with previously treated germ cell tumors: results and prognostic factor analysis. *J Clin Oncol* 2010;28:1706-1713.
- <sup>3</sup> Bokemeyer C, Oechsle K, Honecker F, et al; German Testicular Cancer Study Group. Combination chemotherapy with gemcitabine, oxaliplatin, and paclitaxel in patients with cisplatin-refractory or multiply relapsed germ-cell tumors: A study of the German Testicular Cancer Study Group. *Ann Oncol* 2008;19:448-453.
- <sup>4</sup> Pectasides D, Pectasides M, Farmakis D, et al. Gemcitabine and oxaliplatin (GEMOX) in patients with cisplatin-refractory germ cell tumors: a phase II study. *Ann Oncol* 2004;15:493-497.
- <sup>5</sup> Kollmannsberger C, Beyer J, Liersch R, et al. Combination chemotherapy with gemcitabine plus oxaliplatin in patients with intensively pretreated or refractory germ cell cancer: a study of the German Testicular Cancer Study Group. *J Clin Oncol* 2004;22:108-114.
- <sup>6</sup> De Giorgi U, Rosti G, Aieta M, et al. Phase II study of oxaliplatin and gemcitabine salvage chemotherapy in patients with cisplatin-refractory nonseminomatous germ cell tumor. *Eur Urol* 2006;50:1032-1038.
- <sup>7</sup> Einhorn LH, Brames MJ, Juliar B, Williams SD. Phase II study of paclitaxel plus gemcitabine salvage chemotherapy for germ cell tumors after progression following high-dose chemotherapy with tandem transplant. *J Clin Oncol* 2007;25:513-516.
- <sup>8</sup> Mulherin BP, Brames MJ, Einhorn LH. Long-term survival with paclitaxel and gemcitabine for germ cell tumors after progression following high-dose chemotherapy with tandem transplant. *Am J Clin Oncol* 2015;38:373-376.
- <sup>9</sup> Miller JC, Einhorn LH. Phase II study of daily oral etoposide in refractory germ cell tumors. *Semin Oncol* 1990;17:36-39.
- <sup>10</sup> Le DT, Durham JN, Smith KN, et al. Mismatch repair deficiency predicts response of solid tumors to PD-1 blockade. *Science* 2017;357:409-413.
- <sup>11</sup> Le DT, Uram JN, Wang H, et al. PD-1 blockade in tumors with mismatch-repair deficiency. *N Engl J Med* 2015;372:2509-2520.

Version 2.2020, 11/20/19 © National Comprehensive Cancer Network, Inc. 2019. All rights reserved.  
The NCCN Guidelines® and this illustration may not be reproduced in any form without the express written permission of NCCN.

TEST-G  
3 OF 3

pembrolizumab in patients with metastatic or refractory testicular cancers are needed to fully assess the value of this therapy, especially in treating MSI-H/dMMR testicular GCTs.

### Treatment of Brain Metastases

Brain metastases from testicular GCTs are relatively rare and occur almost exclusively in patients with non-seminoma histology.<sup>133</sup> The development of brain metastases may be more common in patients with a higher burden of systemic disease; lung, liver, and/or bone metastases; high levels of serum beta-hCG (>5,000 IU/L); and in those who experience relapse after cisplatin-based chemotherapy. The prognosis of patients with brain metastases from testicular GCTs is poor, with >50% of patients dying within 1 year of diagnosis.<sup>133,134</sup> Patients with additional adverse prognostic factors, especially those with metachronous brain metastases, have even worse outcomes.<sup>133,135,136</sup>

In a recent retrospective analysis, Loriot et al<sup>137</sup> reported on the pattern of relapse among patients with poor-risk nonseminomatous GCTs previously treated with chemotherapy. After a median follow-up of 4.1 years, 32% were found to have radiographic evidence of brain metastases. The brain was the only site of progression in

54% of these patients, and 19% experienced progression in the brain as the first progression event. Furthermore, involvement of the brain was more common among patients who were previously treated with high-dose chemotherapy (29%) compared with BEP (12%). These data suggest that brain metastases from testicular GCTs may occur more frequently than previously thought, often as the only site of progression, and may be more likely to occur in poor-risk patients previously treated with high-dose chemotherapy. However, it is unknown whether this effect was due to the lower cerebral drug penetrance of the high-dose regimen.

The optimal management of brain metastases from testicular GCTs is controversial, with a lack of evidence from prospective trials to guide treatment decisions.<sup>133,135</sup> Therefore, management decisions are usually based on institutional preferences, which may in part explain the large variation in treatment modalities received by these patients. The NCCN Guidelines recommend primary treatment with cisplatin-based chemotherapy for patients with brain metastases. The addition of radiation therapy to chemotherapy regimens can also be considered.<sup>138</sup> Surgical resection of metastatic brain lesions should be performed if clinically indicated and feasible.

## Summary

The NCCN Guidelines for Testicular Cancer provide an evidence- and consensus-based treatment approach for the management of adult patients with seminomatous and nonseminomatous testicular GCTs. Testicular GCTs are sensitive to platinum-based chemotherapy, and patients have high cure rates even with metastatic disease. Although most metastatic GCTs are cured with chemotherapy, 20% to 30% of patients will experience relapse after first-line chemotherapy and require additional treatment strategies. The ongoing international phase III TIGER trial aims to determine whether high-dose or conventional-dose chemotherapy is more effective in the second-line setting for patients with relapsed disease.

Patients with platinum-refractory or relapsing tumors after second-line therapy have very poor outcomes despite salvage treatments, with no effective alternative therapies. Targeted therapies appear to have limited activity in this setting, although more robust clinical trials are needed to assess their value in treating testicular GCTs. Prognosis for patients with brain metastases remains poor, with a lack of evidence from prospective trials to guide treatment decisions. Therefore, the NCCN panel encourages patients with metastatic, recurrent, or platinum-refractory testicular GCTs to participate in well-designed clinical trials investigating novel therapeutic strategies to enable further advances for the management of this disease.

## References

1. Cancer Statistics Factsheets SEER. Testicular Cancer. National Cancer Institute, Bethesda, MD. 2019. Available at: <https://seer.cancer.gov/statfacts/html/testis.html>. Accessed September 5, 2019.
2. Sarici H, Telli O, Eroglu M. Bilateral testicular germ cell tumors. *Turk J Urol* 2013;39:249–252.
3. Huyghe E, Matsuda T, Thonneau P. Increasing incidence of testicular cancer worldwide: a review. *J Urol* 2003;170:5–11.
4. Shanmugalingam T, Soultati A, Chowdhury S, et al. Global incidence and outcome of testicular cancer. *Clin Epidemiol* 2013;5:417–427.
5. Verhoeven RH, Gondos A, Janssen-Heijnen ML, et al. Testicular cancer in Europe and the USA: survival still rising among older patients. *Ann Oncol* 2013;24:508–513.
6. Chia VM, Quraishi SM, Devesa SS, et al. International trends in the incidence of testicular cancer, 1973-2002. *Cancer Epidemiol Biomarkers Prev* 2010;19:1151–1159.
7. Pishgar F, Haj-Mirzaian A, Ebrahimi H, et al. Global, regional and national burden of testicular cancer, 1990-2016: results from the Global Burden of Disease Study 2016. *BJU Int* 2019;124:386–394.
8. Siegel RL, Miller KD, Jemal A. Cancer statistics, 2019. *CA Cancer J Clin* 2019;69:7–34.
9. Turnbull C, Rahman N. Genome-wide association studies provide new insights into the genetic basis of testicular germ-cell tumour. *Int J Androl* 2011;34:e86–e97.
10. Greene MH, Kratz CP, Mai PL, et al. Familial testicular germ cell tumors in adults: 2010 summary of genetic risk factors and clinical phenotype. *Endocr Relat Cancer* 2010;17:R109–R121.
11. Vasdev N, Moon A, Thorpe AC. Classification, epidemiology and therapies for testicular germ cell tumours. *Int J Dev Biol* 2013;57:133–139.
12. Amin MB, Edge SB, Greene F, et al., editors. *AJCC Cancer Staging Manual*, 8th Ed. New York, NY: Springer International Publishing; 2017. <https://doi.org/10.1007/978-3-319-40618-3>
13. Gilligan TD, Seidenfeld J, Basch EM, et al. American Society of Clinical Oncology Clinical Practice Guideline on uses of serum tumor markers in adult males with germ cell tumors. *J Clin Oncol* 2010;28:3388–3404.
14. Ferraro S, Trevisiol C, Gion M, et al. Human chorionic gonadotropin assays for testicular tumors: closing the gap between clinical and laboratory practice. *Clin Chem* 2018;64:270–278.
15. Lempiäinen A, Hotakainen K, Blomqvist C, et al. Increased human chorionic gonadotropin due to hypogonadism after treatment of a testicular seminoma. *Clin Chem* 2007;53:1560–1561.
16. Morris MJ, Bosl GJ. Recognizing abnormal marker results that do not reflect disease in patients with germ cell tumors. *J Urol* 2000;163:796–801.
17. Trojan A, Joller-Jemelka H, Stahel RA, et al. False-positive human serum chorionic gonadotropin in a patient with a history of germ cell cancer. *Oncology* 2004;66:336–338.
18. Ballieux BE, Weijl NI, Gelderblom H, et al. False-positive serum human chorionic gonadotropin (HCG) in a male patient with a malignant germ cell tumor of the testis: a case report and review of the literature. *Oncologist* 2008;13:1149–1154.
19. Nazeer T, Ro JY, Amato RJ, et al. Histologically pure seminoma with elevated alpha-fetoprotein: a clinicopathologic study of ten cases. *Oncol Rep* 1998;5:1425–1429.
20. Kundu SD, Carver BS, Sheinfeld J. Retroperitoneal histologic findings of patients with elevated serum alpha-fetoprotein and pure seminoma at orchiectomy. *Urology* 2011;78:844–847.
21. Salem M, Gilligan T. Serum tumor markers and their utilization in the management of germ-cell tumors in adult males. *Expert Rev Anticancer Ther* 2011;11:1–4.
22. Kim W, Rosen MA, Langer JE, et al. US MR imaging correlation in pathologic conditions of the scrotum. *Radiographics* 2007;27:1239–1253.
23. Jones RH, Vasey PA. Part I: testicular cancer—management of early disease. *Lancet Oncol* 2003;4:730–737.
24. Dieckmann KP, Anheuser P, Schmidt S, et al. Testicular prostheses in patients with testicular cancer - acceptance rate and patient satisfaction. *BMC Urol* 2015;15:16.
25. Robinson R, Tait CD, Clarke NW, et al. Is it safe to insert a testicular prosthesis at the time of radical orchiectomy for testis cancer: an audit of 904 men undergoing radical orchiectomy. *BJU Int* 2016;117:249–252.
26. Yossepowitch O, Aviv D, Wainchwaig L, et al. Testicular prostheses for testis cancer survivors: patient perspectives and predictors of long-term satisfaction. *J Urol* 2011;186:2249–2252.
27. Fosså SD, Chen J, Schonfeld SJ, et al. Risk of contralateral testicular cancer: a population-based study of 29,515 U.S. men. *J Natl Cancer Inst* 2005;97:1056–1066.
28. Ragni G, Somigliana E, Restelli L, et al. Sperm banking and rate of assisted reproduction treatment: insights from a 15-year cryopreservation program for male cancer patients. *Cancer* 2003;97:1624–1629.
29. Saito K, Suzuki K, Iwasaki A, et al. Sperm cryopreservation before cancer chemotherapy helps in the emotional battle against cancer. *Cancer* 2005;104:521–524.
30. Brydøy M, Fosså SD, Klepp O, et al. Paternity following treatment for testicular cancer. *J Natl Cancer Inst* 2005;97:1580–1588.
31. Huyghe E, Matsuda T, Daudin M, et al. Fertility after testicular cancer treatments: results of a large multicenter study. *Cancer* 2004;100:732–737.
32. Paner GP, Stadler WM, Hansel DE, et al. Updates in the eighth edition of the tumor-node-metastasis staging classification for urologic cancers. *Eur Urol* 2018;73:560–569.
33. Yilmaz A, Cheng T, Zhang J, et al. Testicular hilum and vascular invasion predict advanced clinical stage in nonseminomatous germ cell tumors. *Mod Pathol* 2013;26:579–586.
34. Trevino KE, Esmaeili-Shandiz A, Saeed O, et al. Pathological risk factors for higher clinical stage in testicular seminomas. *Histopathology* 2018;73:741–747.

35. Tandstad T, Ståhl O, Håkansson U, et al. One course of adjuvant BEP in clinical stage I nonseminoma mature and expanded results from the SWENOTECA group. *Ann Oncol* 2014;25:2167–2172.
36. Ernst DS, Brasher P, Venner PM, et al. Compliance and outcome of patients with stage 1 non-seminomatous germ cell tumors (NSGCT) managed with surveillance programs in seven Canadian centres. *Can J Urol* 2005;12:2575–2580.
37. Lago-Hernandez CA, Feldman H, O'Donnell E, et al. A refined risk stratification scheme for clinical stage 1 NSGCT based on evaluation of both embryonal predominance and lymphovascular invasion. *Ann Oncol* 2015;26:1396–1401.
38. Kobayashi K, Saito T, Kitamura Y, et al. Oncological outcomes in patients with stage I testicular seminoma and nonseminoma: pathological risk factors for relapse and feasibility of surveillance after orchiectomy. *Diagn Pathol* 2013;8:57.
39. Soper MS, Hastings JR, Cosmatos HA, et al. Observation versus adjuvant radiation or chemotherapy in the management of stage I seminoma: clinical outcomes and prognostic factors for relapse in a large US cohort. *Am J Clin Oncol* 2014;37:356–359.
40. Sturgeon JF, Moore MJ, Kakiashvili DM, et al. Non-risk-adapted surveillance in clinical stage I nonseminomatous germ cell tumors: the Princess Margaret Hospital's experience. *Eur Urol* 2011;59:556–562.
41. Leman ES, Gonzalgo ML. Prognostic features and markers for testicular cancer management. *Indian J Urol* 2010;26:76–81.
42. Gordetsky J, Sanfrancesco J, Epstein JI, et al. Do nonseminomatous germ cell tumors of the testis with lymphovascular invasion of the spermatic cord merit staging as pT3? *Am J Surg Pathol* 2017;41:1397–1402.
43. Nazeer T, Ro JY, Kee KH, et al. Spermatic cord contamination in testicular cancer. *Mod Pathol* 1996;9:762–766.
44. Divrik RT, Akdoğan B, Ozen H, et al. Outcomes of surveillance protocol of clinical stage I nonseminomatous germ cell tumors—is shift to risk adapted policy justified? *J Urol* 2006;176:1424–1429., discussion 1429–1430.
45. Gilbert DC, Al-Saadi R, Thway K, et al. Defining a new prognostic index for stage I nonseminomatous germ cell tumors using CXCL12 expression and proportion of embryonal carcinoma. *Clin Cancer Res* 2016;22:1265–1273.
46. Vergouwe Y, Steyerberg EW, Eijkemans MJ, et al. Predictors of occult metastasis in clinical stage I nonseminoma: a systematic review. *J Clin Oncol* 2003;21:4092–4099.
47. Daugaard G, Gundgaard MG, Mortensen MS, et al. Surveillance for stage I nonseminoma testicular cancer: outcomes and long-term follow-up in a population-based cohort. *J Clin Oncol* 2014;32:3817–3823.
48. Heidenreich A, Sesterhenn IA, Mostofi FK, et al. Prognostic risk factors that identify patients with clinical stage I nonseminomatous germ cell tumors at low risk and high risk for metastasis. *Cancer* 1998;83:1002–1011.
49. Alexandre J, Fizazi K, Mahé C, et al. Stage I non-seminomatous germ-cell tumours of the testis: identification of a subgroup of patients with a very low risk of relapse. *Eur J Cancer* 2001;37:576–582.
50. Sweeney CJ, Hermans BP, Heilman DK, et al. Results and outcome of retroperitoneal lymph node dissection for clinical stage I embryonal carcinoma—predominant testis cancer. *J Clin Oncol* 2000;18:358–362.
51. Albers P, Siener R, Kliesch S, et al. Risk factors for relapse in clinical stage I nonseminomatous testicular germ cell tumors: results of the German Testicular Cancer Study Group Trial. *J Clin Oncol* 2003;21:1505–1512.
52. Sanfrancesco JM, Trevino KE, Xu H, et al. The significance of spermatic cord involvement by testicular germ cell tumors: should we be staging discontinuous invasion from involved lymphovascular spaces differently from direct extension? *Am J Surg Pathol* 2018;42:306–311.
53. de Wit M, Brenner W, Hartmann M, et al. [18F]-FDG-PET in clinical stage I/II non-seminomatous germ cell tumours: results of the German multicentre trial. *Ann Oncol* 2008;19:1619–1623.
54. Huddart RA, O'Doherty MJ, Padhani A, et al. 18fluorodeoxyglucose positron emission tomography in the prediction of relapse in patients with high-risk, clinical stage I nonseminomatous germ cell tumors: preliminary report of MRC Trial TE22—the NCRI Testis Tumour Clinical Study Group. *J Clin Oncol* 2007;25:3090–3095.
55. Nonomura N, Nishimura K, Takaha N, et al. Nerve-sparing retroperitoneal lymph node dissection for advanced testicular cancer after chemotherapy. *Int J Urol* 2002;9:539–544.
56. Calaway AC, Einhorn LH, Masterson TA, et al. Adverse surgical outcomes associated with robotic retroperitoneal lymph node dissection among patients with testicular cancer. *Eur Urol* 2019;76:607–609.
57. Punjani N, Winquist E, Power N. Do retroperitoneal extragonadal germ cell tumours exist? *Can Urol Assoc J* 2015;9:381–384.
58. Zuniga A, Kakiashvili D, Jewett MA. Surveillance in stage I non-seminomatous germ cell tumours of the testis. *BJU Int* 2009; 104(9b, 9 Pt B):1351–1356.
59. Oliver RT, Ong J, Shamash J, et al. Long-term follow-up of Anglian Germ Cell Cancer Group surveillance versus patients with stage 1 nonseminoma treated with adjuvant chemotherapy. *Urology* 2004;63:556–561.
60. Stephenson AJ, Bosl GJ, Bajorin DF, et al. Retroperitoneal lymph node dissection in patients with low stage testicular cancer with embryonal carcinoma predominance and/or lymphovascular invasion. *J Urol* 2005; 174:557–560.
61. Albers P, Siener R, Krega S, et al. Randomized phase III trial comparing retroperitoneal lymph node dissection with one course of bleomycin and etoposide plus cisplatin chemotherapy in the adjuvant treatment of clinical stage I nonseminomatous testicular germ cell tumors: AJO trial AH 01/94 by the German Testicular Cancer Study Group. *J Clin Oncol* 2008;26:2966–2972.
62. Tandstad T, Dahl O, Cohn-Cedermark G, et al. Risk-adapted treatment in clinical stage I nonseminomatous germ cell testicular cancer: the SWENOTECA management program. *J Clin Oncol* 2009;27: 2122–2128.
63. Stephenson AJ, Bosl GJ, Motzer RJ, et al. Retroperitoneal lymph node dissection for nonseminomatous germ cell testicular cancer: impact of patient selection factors on outcome. *J Clin Oncol* 2005;23:2781–2788.
64. Böhlen D, Burkhard FC, Mills R, et al. Fertility and sexual function following orchiectomy and 2 cycles of chemotherapy for stage I high risk nonseminomatous germ cell cancer. *J Urol* 2001;165:441–444.
65. Chevreau C, Mazerolles C, Soulié M, et al. Long-term efficacy of two cycles of BEP regimen in high-risk stage I nonseminomatous testicular germ cell tumors with embryonal carcinoma and/or vascular invasion. *Eur Urol* 2004;46:209–215.
66. De La Pena H, Sharma A, Glicksman C, et al. No longer any role for routine follow-up chest x-rays in men with stage I germ cell cancer. *Eur J Cancer* 2017;84:354–359.
67. Gietema JA, Meinardi MT, Sleijfer DT, et al. Routine chest X-rays have no additional value in the detection of relapse during routine follow-up of patients treated with chemotherapy for disseminated non-seminomatous testicular cancer. *Ann Oncol* 2002;13:1616–1620.
68. Kollmannsberger C, Tandstad T, Bedard PL, et al. Patterns of relapse in patients with clinical stage I testicular cancer managed with active surveillance. *J Clin Oncol* 2015;33:51–57.
69. Bamias A, Aravantinos G, Kastriotis I, et al. Report of the long-term efficacy of two cycles of adjuvant bleomycin/etoposide/cisplatin in patients with stage I testicular nonseminomatous germ-cell tumors (NSGCT): a risk adapted protocol of the Hellenic Cooperative Oncology Group. *Urol Oncol* 2011;29:189–193.
70. Guney S, Guney N, Sonmez NC, et al. Risk-adapted management for patients with clinical stage I non-seminomatous germ cell tumour of the testis. *Med Oncol* 2009;26:136–142.
71. Chovanec M, Hanna N, Cary KC, et al. Management of stage I testicular germ cell tumours. *Nat Rev Urol* 2016;13:663–673.
72. Huddart RA, Reid AM. Adjuvant therapy for stage IB germ cell tumors: one versus two cycles of BEP. *Adv Urol* 2018;2018:8781698.
73. Meinardi MT, Gietema JA, van der Graaf WT, et al. Cardiovascular morbidity in long-term survivors of metastatic testicular cancer. *J Clin Oncol* 2000;18:1725–1732.
74. Chovanec M, Abu Zaid M, Hanna N, et al. Long-term toxicity of cisplatin in germ-cell tumor survivors. *Ann Oncol* 2017;28:2670–2679.
75. Strumberg D, Brüggé S, Korn MW, et al. Evaluation of long-term toxicity in patients after cisplatin-based chemotherapy for non-seminomatous testicular cancer. *Ann Oncol* 2002;13:229–236.
76. Fung C, Dinh P, Jr., Ardesir-Rouhani-Fard S, et al. Toxicities associated with cisplatin-based chemotherapy and radiotherapy in long-term testicular cancer survivors. *Adv Urol* 2018;2018:8671832.
77. Hartmann JT, Lipp HP. Toxicity of platinum compounds. *Expert Opin Pharmacother* 2003;4:889–901.
78. Kerns SL, Fung C, Monahan PO, et al. Cumulative burden of morbidity among testicular cancer survivors after standard cisplatin-based chemotherapy: a multi-institutional study. *J Clin Oncol* 2018;36: 1505–1512.
79. Sprauten M, Darrah TH, Peterson DR, et al. Impact of long-term serum platinum concentrations on neuro- and ototoxicity in cisplatin-treated survivors of testicular cancer. *J Clin Oncol* 2012;30: 300–307.



80. Haugnes HS, Stenklev NC, Brydøy M, et al. Hearing loss before and after cisplatin-based chemotherapy in testicular cancer survivors: a longitudinal study. *Acta Oncol* 2018;57:1075–1083.
81. Raphael MJ, Wei X, Karim S, et al. Neurotoxicity among survivors of testicular cancer: a population-based study. *Clin Oncol (R Coll Radiol)* 2019;31:653–658.
82. Lv ZJ, Wu S, Dong P, et al. Clinical outcomes in patients with stage I non-seminomatous germ cell cancer. *Asian J Androl* 2013;15:558–563.
83. Mezvrishvili Z, Managadze L. Three cycles of etoposide and cisplatin chemotherapy in clinical stage IS nonseminomatous testicular cancer. *Int Urol Nephrol* 2006;38:621–624.
84. Stephenson AJ, Bosl GJ, Motzer RJ, et al. Nonrandomized comparison of primary chemotherapy and retroperitoneal lymph node dissection for clinical stage IIA and IIB nonseminomatous germ cell testicular cancer. *J Clin Oncol* 2007;25:5597–5602.
85. Weissbach L, Bussar-Maatz R, Flechtner H, et al. RPLND or primary chemotherapy in clinical stage IIA/B nonseminomatous germ cell tumors? Results of a prospective multicenter trial including quality of life assessment. *Eur Urol* 2000;37:582–594.
86. Rabbani F, Sheinfeld J, Farivar-Mohseni H, et al. Low-volume nodal metastases detected at retroperitoneal lymphadenectomy for testicular cancer: pattern and prognostic factors for relapse. *J Clin Oncol* 2021;39:2020–2025.
87. Sheinfeld J, Motzer RJ, Rabbani F, et al. Incidence and clinical outcome of patients with teratoma in the retroperitoneum following primary retroperitoneal lymph node dissection for clinical stages I and IIA nonseminomatous germ cell tumors. *J Urol* 2003;170:1159–1162.
88. Stephenson AJ, Klein EA. Surgical management of low-stage non-seminomatous germ cell testicular cancer. *BJU Int* 2009;104:1362–1368.
89. Behnia M, Foster R, Einhorn LH, et al. Adjuvant bleomycin, etoposide and cisplatin in pathological stage II non-seminomatous testicular cancer: the Indiana University experience. *Eur J Cancer* 2000;36:472–475.
90. Kondagunta GV, Sheinfeld J, Mazumdar M, et al. Relapse-free and overall survival in patients with pathologic stage II nonseminomatous germ cell cancer treated with etoposide and cisplatin adjuvant chemotherapy. *J Clin Oncol* 2004;22:464–467.
91. Carver BS, Shayegan B, Eggner S, et al. Incidence of metastatic nonseminomatous germ cell tumor outside the boundaries of a modified postchemotherapy retroperitoneal lymph node dissection. *J Clin Oncol* 2007;25:4365–4369.
92. Horwich A, Norman A, Fisher C, et al. Primary chemotherapy for stage II nonseminomatous germ cell tumors of the testis. *J Urol* 1994;151:72–78.
93. Donohue JP, Thornhill JA, Foster RS, et al. The role of retroperitoneal lymphadenectomy in clinical stage B testis cancer: the Indiana University experience (1965 to 1989). *J Urol* 1995;153:85–89.
94. International Germ Cell Cancer Collaborative Group. International Germ Cell Consensus Classification: a prognostic factor-based staging system for metastatic germ cell cancers. *J Clin Oncol* 1997;15:594–603.
95. de Wit R, Roberts JT, Wilkinson PM, et al. Equivalence of three or four cycles of bleomycin, etoposide, and cisplatin chemotherapy and of a 3- or 5-day schedule in good-prognosis germ cell cancer: a randomized study of the European Organization for Research and Treatment of Cancer Genitourinary Tract Cancer Cooperative Group and the Medical Research Council. *J Clin Oncol* 2001;19:1629–1640.
96. Culine S, Kerbrat P, Kramar A, et al. Refining the optimal chemotherapy regimen for good-risk metastatic nonseminomatous germ-cell tumors: a randomized trial of the Genito-Urinary Group of the French Federation of Cancer Centers (GETUG T93BP). *Ann Oncol* 2007;18:917–924.
97. Cary C, Jacob JM, Albany C, et al. Long-term survival of good-risk germ cell tumor patients after postchemotherapy retroperitoneal lymph node dissection: a comparison of BEP x 3 vs EP x 4 and treating institution. *Clin Genitourin Cancer* 2018;16:e307–e313.
98. Kondagunta GV, Bacik J, Bajorin D, et al. Etoposide and cisplatin chemotherapy for metastatic good-risk germ cell tumors. *J Clin Oncol* 2005;23:9290–9294.
99. Jones RH, Vasey PA. Part II: testicular cancer—management of advanced disease. *Lancet Oncol* 2003;4:738–747.
100. de Wit R, Stoter G, Sleijfer DT, et al. Four cycles of BEP vs four cycles of VIP in patients with intermediate-prognosis metastatic testicular non-seminoma: a randomized study of the EORTC Genitourinary Tract Cancer Cooperative Group. *Br J Cancer* 1998;78:828–832.
101. Culine S, Kramar A, Théodore C, et al. Randomized trial comparing bleomycin/etoposide/cisplatin with alternating cisplatin/cyclophosphamide/doxorubicin and vinblastine/bleomycin regimens of chemotherapy for patients with intermediate- and poor-risk metastatic nonseminomatous germ cell tumors: Genito-Urinary Group of the French Federation of Cancer Centers Trial T93MP. *J Clin Oncol* 2008;26:421–427.
102. Nichols CR, Catalano PJ, Crawford ED, et al. Randomized comparison of cisplatin and etoposide and either bleomycin or ifosfamide in treatment of advanced disseminated germ cell tumors: an Eastern Cooperative Oncology Group, Southwest Oncology Group, and Cancer and Leukemia Group B Study. *J Clin Oncol* 1998;16:1287–1293.
103. van Dijk MR, Steyerberg EW, Habbema JD. Survival of non-seminomatous germ cell cancer patients according to the IGCC classification: an update based on meta-analysis. *Eur J Cancer* 2006;42:820–826.
104. Kollmannsberger C, Daneshmand S, So A, et al. Management of disseminated nonseminomatous germ cell tumors with risk-based chemotherapy followed by response-guided postchemotherapy surgery. *J Clin Oncol* 2010;28:537–542.
105. Schmidt AH, Hoyer M, Jensen BFS, et al. Limited post-chemotherapy retroperitoneal resection of residual tumour in non-seminomatous testicular cancer: complications, outcome and quality of life. *Acta Oncol* 2018;57:1084–1093.
106. Heidenreich A, Haidl F, Paffenholz P, et al. Surgical management of complex residual masses following systemic chemotherapy for metastatic testicular germ cell tumours. *Ann Oncol* 2017;28:362–367.
107. Daneshmand S, Albers P, Fosså SD, et al. Contemporary management of postchemotherapy testis cancer. *Eur Urol* 2012;62:867–876.
108. Riggs SB, Burgess EF, Gaston KE, et al. Postchemotherapy surgery for germ cell tumors—what have we learned in 35 years? *Oncologist* 2014;19:498–506.
109. Loehrer PJ, Sr., Gonin R, Nichols CR, et al. Vinblastine plus ifosfamide plus cisplatin as initial salvage therapy in recurrent germ cell tumor. *J Clin Oncol* 1998;16:2500–2504.
110. Kondagunta GV, Bacik J, Donadio A, et al. Combination of paclitaxel, ifosfamide, and cisplatin is an effective second-line therapy for patients with relapsed testicular germ cell tumors. *J Clin Oncol* 2005;23:6549–6555.
111. Park S, Lee S, Lee J, et al. Salvage chemotherapy with paclitaxel, ifosfamide, and cisplatin (TIP) in relapsed or cisplatin-refractory germ cell tumors. *Onkologie* 2011;34:416–420.
112. Kurobe M, Kawai K, Oikawa T, et al. Paclitaxel, ifosfamide, and cisplatin (TIP) as salvage and consolidation chemotherapy for advanced germ cell tumor. *J Cancer Res Clin Oncol* 2015;141:127–133.
113. Einhorn LH, Williams SD, Channess A, et al. High-dose chemotherapy and stem-cell rescue for metastatic germ-cell tumors. *N Engl J Med* 2007;357:340–348.
114. Feldman DR, Sheinfeld J, Bajorin DF, et al. TI-CE high-dose chemotherapy for patients with previously treated germ cell tumors: results and prognostic factor analysis. *J Clin Oncol* 2010;28:1706–1713.
115. Albers P, Ganz A, Hannig E, et al. Salvage surgery of chemorefractory germ cell tumors with elevated tumor markers. *J Urol* 2000;164:381–384.
116. George DW, Foster RS, Hromas RA, et al. Update on late relapse of germ cell tumor: a clinical and molecular analysis. *J Clin Oncol* 2003;21:113–122.
117. Lipphardt ME, Albers P. Late relapse of testicular cancer. *World J Urol* 2004;22:47–54.
118. Oing C, Lorch A, Bokemeyer C. Ongoing clinical trials in testicular cancer: the TIGER trial. *Oncol Res Treat* 2016;39:553–556.
119. Lorch A, Bascoul-Mollevi C, Kramar A, et al. Conventional-dose versus high-dose chemotherapy as first salvage treatment in male patients with metastatic germ cell tumors: evidence from a large international database. *J Clin Oncol* 2011;29:2178–2184.
120. McHugh DJ, Feldman DR. Conventional-dose versus high-dose chemotherapy for relapsed germ cell tumors. *Adv Urol* 2018;2018:7272541.
121. Bokemeyer C, Oechsle K, Honecker F, et al. Combination chemotherapy with gemcitabine, oxaliplatin, and paclitaxel in patients with cisplatin-refractory or multiply relapsed germ-cell tumors: a study of the German Testicular Cancer Study Group. *Ann Oncol* 2008;19:448–453.
122. De Giorgi U, Rosti G, Aieta M, et al. Phase II study of oxaliplatin and gemcitabine salvage chemotherapy in patients with cisplatin-refractory nonseminomatous germ cell tumor. *Eur Urol* 2006;50:1032–1039.
123. Einhorn LH, Brame MJ, Juliar B, et al. Phase II study of paclitaxel plus gemcitabine salvage chemotherapy for germ cell tumors after progression following high-dose chemotherapy with tandem transplant. *J Clin Oncol* 2007;25:513–516.



124. Kollmannsberger C, Beyer J, Liersch R, et al. Combination chemotherapy with gemcitabine plus oxaliplatin in patients with intensively pretreated or refractory germ cell cancer: a study of the German Testicular Cancer Study Group. *J Clin Oncol* 2004;22:108–114.
125. Mulherin BP, Brames MJ, Einhorn LH. Long-term survival with paclitaxel and gemcitabine for germ cell tumors after progression following high-dose chemotherapy with tandem transplant. *Am J Clin Oncol* 2015;38:373–376.
126. Pectasides D, Pectasides M, Farmakis D, et al. Gemcitabine and oxaliplatin (GEMOX) in patients with cisplatin-refractory germ cell tumors: a phase II study. *Ann Oncol* 2004;15:493–497.
127. Seidel C, Oechsle K, Lorch A, et al. Efficacy and safety of gemcitabine, oxaliplatin, and paclitaxel in cisplatin-refractory germ cell cancer in routine care—registry data from an outcomes research project of the German Testicular Cancer Study Group. *Urol Oncol* 2016;34:167.e21–167.e28.
128. Miller JC, Einhorn LH. Phase II study of daily oral etoposide in refractory germ cell tumors. *Semin Oncol* 1990; 17(1, Suppl 2)36–39.
129. U.S. Food and Drug Administration. FDA grants accelerated approval to pembrolizumab for first tissue/site agnostic indication. 2017. Available at: <https://www.fda.gov/drugs/informationondrugs/approveddrugs/ucm560040.htm>. Accessed October 7, 2019.
130. Le DT, Durham JN, Smith KN, et al. Mismatch repair deficiency predicts response of solid tumors to PD-1 blockade. *Science* 2017; 357:409–413.
131. Le DT, Uram JN, Wang H, et al. PD-1 blockade in tumors with mismatch-repair deficiency. *N Engl J Med* 2015;372:2509–2520.
132. Adra N, Einhorn LH, Althouse SK, et al. Phase II trial of pembrolizumab in patients with platinum refractory germ-cell tumors: a Hoosier Cancer Research Network Study GU14-206. *Ann Oncol* 2018;29:209–214.
133. Feldman DR, Lorch A, Kramar A, et al. Brain metastases in patients with germ cell tumors: prognostic factors and treatment options—an analysis from the global germ cell cancer group. *J Clin Oncol* 2016;34:345–351.
134. Schmoll HJ, Souchon R, Krega S, et al. European consensus on diagnosis and treatment of germ cell cancer: a report of the European Germ Cell Cancer Consensus Group (EGCCCG). *Ann Oncol* 2004;15:1377–1399.
135. Beyer J, Albers P, Altena R, et al. Maintaining success, reducing treatment burden, focusing on survivorship: highlights from the third European consensus conference on diagnosis and treatment of germ-cell cancer. *Ann Oncol* 2013;24:878–888.
136. Boyle HJ, Jouanneau E, Droz JP, et al. Management of brain metastases from germ cell tumors: a single center experience. *Oncology* 2013;85: 21–26.
137. Lortot Y, Pagliaro L, Fléchon A, et al. Patterns of relapse in poor-prognosis germ-cell tumours in the GETUG 13 trial: Implications for assessment of brain metastases. *Eur J Cancer* 2017;87:140–146.
138. Kollmannsberger C, Nichols C, Bamberg M, et al. First-line high-dose chemotherapy +/- radiation therapy in patients with metastatic germ-cell cancer and brain metastases. *Ann Oncol* 2000;11:553–559.

## Individual Disclosures for the NCCN Testicular Cancer Panel

Panel Member	Clinical Research Support/Data Safety Monitoring Board	Scientific Advisory Boards, Consultant, or Expert Witness	Promotional Advisory Boards, Consultant, or Speakers Bureau	Specialties
Rahul Aggarwal, MD	Janssen Pharmaceutica Products, LP; Merck & Co., Inc.; Novartis Pharmaceuticals Corporation; and Zenith Epigenetics	AstraZeneca Pharmaceuticals LP; and Janssen Pharmaceutica Products, LP	None	Medical Oncology, Hematology/Hematology Oncology, and Internal Medicine
David Chism, MD, MS	None	None	None	Medical Oncology
Nicholas Cost, MD	None	None	None	Urology
Ithaa H. Derweesh, MD	Pfizer Inc.	None	None	Urology
Hamid Enamekhoo, MD	Bristol-Myers Squibb Company; Janssen Pharmaceutica Products, LP; and MedImmune Inc.	Bayer HealthCare; and Exelixis Inc.	None	Medical Oncology
Darren R. Feldman, MD	Astellas Pharma US, Inc.; Decibel; Novartis Pharmaceuticals Corporation; and Seattle Genetics, Inc.	UpToDate	None	Medical Oncology
Daniel M. Geynisman, MD	None	AstraZeneca Pharmaceuticals LP; and Exelixis Inc.	Astellas Pharma US, Inc.	Hematology/Hematology Oncology
Timothy Gilligan MD	None	None	None	Medical Oncology
Steven L. Hancock, MD	None	None	None	Radiotherapy/Radiation Oncology and Internal Medicine
Chad LaGrange, MD	None	Expert witness	None	Urology
Ellis G. Levine, MD*	None	None	None	Medical Oncology
Daniel W. Lin, MD	GenomeDx; Genomic Health, Inc.; MagForce; and MDxHealth, Inc.	Astellas Pharma US, Inc.; Bayer HealthCare; and Clovis Oncology	None	Urology
Thomas Longo, MD	None	None	None	Urology
William Lowrance, MD, MPH	Myriad Genetic Laboratories, Inc.	None	None	Urology
Bradley McGregor, MD	Bristol-Myers Squibb Company; Calithera; Celldex Therapeutics; Exelixis Inc.; and Seattle Genetics, Inc.	EMD Serono; Exelixis Inc; Janssen Pharmaceutica Products, LP; Pfizer Inc.; and Seattle Genetics, Inc.	None	Medical Oncology
Paul Monk, MD	sanofi-aventis U.S.	Janssen Pharmaceutica Products, LP	Astellas Pharma US, Inc.	Medical Oncology
Joel Picus, MD	None	None	None	Hematology/Hematology Oncology
Phillip Pierorazio, MD	None	Urogen Pharmaceutical	None	Urology
Soroush Rais-Bahrami, MD	None	Bayer HealthCare; Blue Earth Diagnostics; Genomic Health, Inc.; and Intuitive Surgical, Inc.	None	Urology
Philip Saylor, MD	None	None	None	Medical Oncology
Kanishka Sircar, MD	None	None	None	Pathology
David C. Smith, MD	Astellas Pharma US, Inc.; Bayer HealthCare; Bristol-Myers Squibb Company; Eli Lilly and Company; ESSA Pharmaceuticals; F. Hoffman La-Roche, AG; Genentech, Inc.; Incyte Corporation; Medarex, Inc.; MedImmune Inc.; Medivation, Inc.; Merck & Co., Inc.; Millennium Pharmaceuticals, Inc.; Novartis Pharmaceuticals Corporation; OncoMed Pharmaceuticals; Pfizer Inc.; and Seattle Genetics, Inc.	None	None	Medical Oncology
Katherine Tzou, MD	None	None	None	Radiotherapy/Radiation Oncology
Daniel Vaena, MD	Aeglea; AstraZeneca Pharmaceuticals LP; Bioclin Therapeutics; Bristol-Myers Squibb Company; Calithera; Compugen; Incyte Corporation; Merck & Co., Inc.; Nektar Therapeutics; Novartis Pharmaceuticals Corporation; OBI Pharma; Peloton Therapeutics, Inc.; TG Therapeutics; and Tizona	Bristol-Myers Squibb Company; Caris; and Genomic Health, Inc.	None	Hematology/Hematology Oncology
David Vaughn, MD	Astellas Pharma US, Inc.; Genentech, Inc.; and Merck & Co., Inc.	Merck & Co., Inc.	None	Medical Oncology
Kosj Yamoah, MD, PhD	None	None	None	Radiotherapy/Radiation Oncology
Jonathan Yamzon, MD	None	None	None	Urology

The NCCN Guidelines Staff have no conflicts to disclose.

\*The following individuals have disclosed that they have an employment/governing board, patent, equity, or royalty for panel member or dependent:

Ellis G. Levine, MD: UpToDate